



CASE REPORT

Coronary artery perforations: Four different cases and a review

Ismail Dogu Kilic^{a,*}, Yusuf Izzettin Alihanoglu^a, Serhat B. Yildiz^b, Ozgur Taskoylu^c,
Mustafa Zungur^d, Ihsan S. Uyar^e, Harun Evrengul^a

^a Pamukkale University, Medical Faculty, Department of Cardiology, 20070 Denizli/Turkey

^b Denizli State Hospital, Department of Cardiology, 20115 Denizli/Turkey

^c Servergazi State Hospital, Department of Cardiology, 20185 Denizli/Turkey

^d Sifa University, Medical Faculty, Department of Cardiology, 35040 Izmir/Turkey

^e Sifa University, Medical Faculty, Department of Cardiovascular Surgery, 35040, Izmir/Turkey

Received 19 February 2013; accepted 21 February 2013

Available online 16 October 2013

KEYWORDS

Coronary artery perforation;
Complication;
Percutaneous coronary intervention

Abstract Coronary artery perforation (CAP) is a rare but feared complication of percutaneous coronary intervention. With the advent of new devices and technologies, interventionalists attempt more complex lesions, including more calcified or tortuous vessels and chronic total occlusions, which increases the incidence of CAP. A short literature review, in addition to four cases of CAP, is presented in this report.

© 2013 Sociedade Portuguesa de Cardiologia Published by Elsevier España, S.L. All rights reserved.

PALAVRAS-CHAVE

Perfurações de artérias coronárias;
Complicação;
Intervenção coronária percutânea

Perfurações de artérias coronárias: quatro casos diferentes e uma revisão

Resumo As perfurações das artérias coronárias são raras, mas complicações temidas nas intervenções coronarianas percutâneas. Com o advento de novos dispositivos e tecnologias, a tentativa de intervenção em lesões mais complexas, incluindo os vasos mais calcificados ou tortuosos ou oclusões crônicas, leva a maior incidência de perfurações de artérias coronárias. Uma breve revisão da literatura, além de quatro casos de perfurações de artérias coronárias foi apresentada no presente trabalho.

© 2013 Sociedade Portuguesa de Cardiologia. Publicado por Elsevier España, S.L. Todos os direitos reservados.

Introduction

Coronary artery perforation (CAP) is a rare but potentially life-threatening complication of percutaneous coronary intervention (PCI). Its incidence depends on the material and methods for visualizing or opening the coronary

* Corresponding author: Pamukkale University Hospital, Department of Cardiology, Denizli/TURKEY.

E-mail address: idogukilic@yahoo.com (I.D. Kilic).

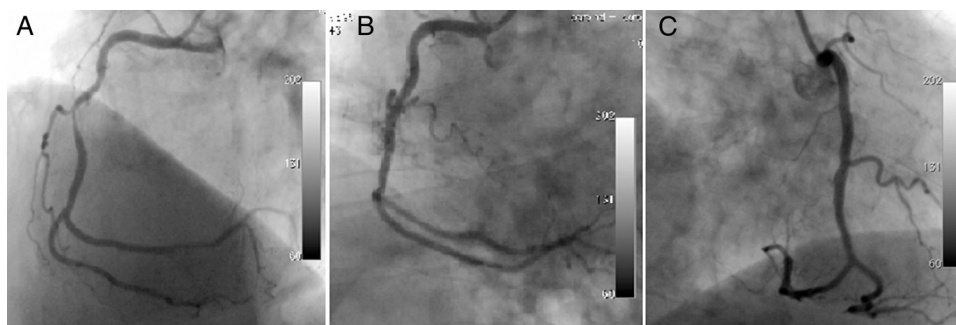


Figure 1 A long, angulated, and eccentric critical lesion in the mid right coronary artery (A); type I coronary perforation limited to the vessel wall without extravasation (B); control angiogram showing no extravasation (C) after prolonged balloon inflation at the ruptured area.

arteries. With the advent of new devices and technologies, interventionalists attempt more complex lesions, including more calcified or tortuous vessels.

The first patient was a 70-year-old man complaining of chest pain despite medical treatment. Coronary angiography (CAG) was performed electively with a diagnosis of stable angina pectoris. CAG revealed a long, angulated, eccentric critical lesion in the mid right coronary artery (Figure 1A). Direct stenting of the target lesion was performed, and then a type I coronary perforation (limited to the vessel wall without extravasation) was detected on the angiogram (Figure 1B). Prolonged balloon inflation only was applied to the ruptured area and the control angiogram showed no extravasation (Figure 1C). There was no pericardial effusion on transthoracic echocardiography after the procedure.

The second patient was a 58-year-old woman who went to the cardiology outpatient clinic with new-onset, progressive, oppressive chest pain, diagnosed as unstable angina. A long, calcified, eccentric critical lesion was detected in the mid to distal left anterior descending (LAD) coronary artery during CAG (Figure 2A). Stenting of the target lesion was performed after balloon predilatation. A type II perforation (showing limited extravasation with some myocardial blushing) was seen on CAG (Figure 2B). A covered stent was immediately implanted to cover the rupture and anticoagulation was reversed. No myocardial blushing was seen on the control CAG (Figure 2C). A mild pericardial effusion, not causing tamponade, was detected by echocardiography.

The third patient was a 47-year-old man, who was referred to the cardiology clinic with chest pain on exercise. Since exercise stress testing showed 3-mm horizontal ST-segment depression at the target heart rate, CAG was scheduled. A long, thin, eccentric and calcified critical lesion was seen in the mid circumflex coronary artery during CAG (Figure 3A). Stenting after balloon predilatation was planned, but a type III coronary rupture (demonstrating significant contrast streaming into the pericardium) was observed while the guidewire was being advanced (Figure 3B). Because a covered stent of suitable size for such a thin lesion was not available in the catheterization laboratory, the patient underwent urgent surgical repair with prolonged balloon inflation proximal to the ruptured area to prevent cardiac tamponade. In addition, reversal of anticoagulation therapy was achieved by protamine.

The fourth patient was a 74-year-old woman who went to the emergency department with new-onset severe chest pain and was diagnosed with acute anterior myocardial infarction. She was transferred to the catheterization laboratory for primary PCI. Long, thin, angulated and eccentric critical sequential lesions with thrombus were detected in the mid to distal portion of the LAD (Figure 4A). After stenting followed by balloon predilatations, prominent contrast flow into the left ventricle was detected on CAG, indicating type IV coronary rupture (Figure 4B). A covered stent was immediately implanted in the ruptured area and anticoagulation was reversed. Control CAG showed no extravasation around the target area (Figure 4C). The echocardiogram

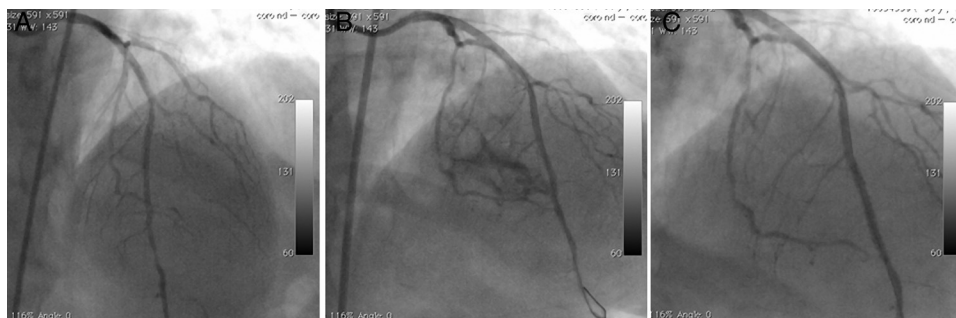


Figure 2 A long, calcified, and eccentric critical lesion in the mid to distal left anterior descending coronary artery (A); type II perforation showing limited extravasation with some myocardial blushing (B); no myocardial blushing is seen on the control angiogram after covered stenting (C).

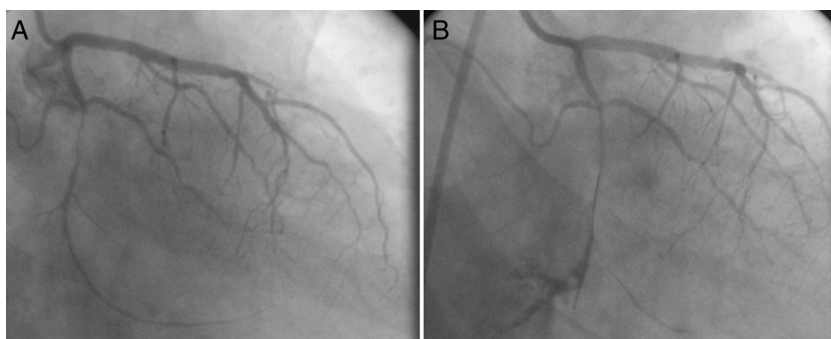


Figure 3 A thin, long, eccentric and calcified critical lesion in the mid circumflex coronary artery (A); guidewire-induced type III coronary rupture demonstrating significant contrast streaming into the pericardium (B).

revealed mild pericardial effusion with no evidence of cardiac tamponade.

The hemodynamic parameters of all of these patients were within normal limits during follow-up and they were discharged fully recovered from the hospital.

Review

CAP is a rare but feared complication of PCI. Its incidence varies according to patient, lesion and procedure characteristics; studies have reported incidences ranging from 0.29 to 3.0%.^{1,2} Risk increases with the complexity of the lesions, including chronic total occlusions, angulated calcified type B2 and type C lesions, long (>10 mm), eccentric lesions, and small vessel size.¹⁻³ Older age and previous coronary artery bypass graft surgery also increase the risk.^{1,4,5} Risk factors include conditions associated with increased calcification such as diabetes, hypertension and chronic renal failure.^{4,6} Although females are thought to be more prone to perforation due to their smaller vasculature, the data are inconsistent.^{7,8}

Ellis et al. classified coronary perforations based on their angiographic appearance.¹ Type I perforations are limited to the vessel wall and produce an intramural crater without extravasation on the angiogram. In contrast to type I, types II and III are not limited to the vessel wall. Type II perforations show limited extravasation with pericardial or myocardial blushing on angiography, whereas in type III prominent contrast streaming from a ≥ 1 -mm tear is seen. In the cavity

spilling subtype (type IV for some authors) contrast flow can be seen from the perforation site into a cardiac chamber or cavity, such as the left ventricle or coronary sinus, rather than into the pericardium or myocardium. Muller et al. proposed adding a type V to the classification, describing distal perforation associated with the use of hydrophilic and/or stiff guides.⁹ Although other classifications are used, Ellis' is the most widely accepted.^{2,10,11}

CAP may occur with the use of guiding catheters, guidewires, oversized balloon/stents, cutting balloons, intravascular ultrasound (IVUS) catheters, or debulking techniques, or following balloon rupture.^{3,12,13} A significant proportion of perforations occur with guidewires crossing the lesion, with distal wire perforation or wire fracture.¹⁴ Physical features of the wire affect the likelihood of CAP. In general, stiffer guides increase the risk of perforation. Likewise, hydrophilic-coated wires have been found to be associated with CAP in some series.^{15,16} However; this may reflect either use of these low-friction hydrophilic coated wires to facilitate passage through more complex lesions or their ease of distal migration.¹⁷

Perforations occur more frequently with debulking techniques than with non-debulking techniques. Considering the mechanism of vessel injury, atheroablative devices often cause type III perforations.¹⁸ Perforation is more likely when IVUS is used, probably because IVUS is frequently used for complex lesions or when PCI is complicated.¹⁹ Whether concomitant administration of GP IIb/IIIa inhibitors increases the likelihood of CAP is controversial, since some studies show increased perforation while others do

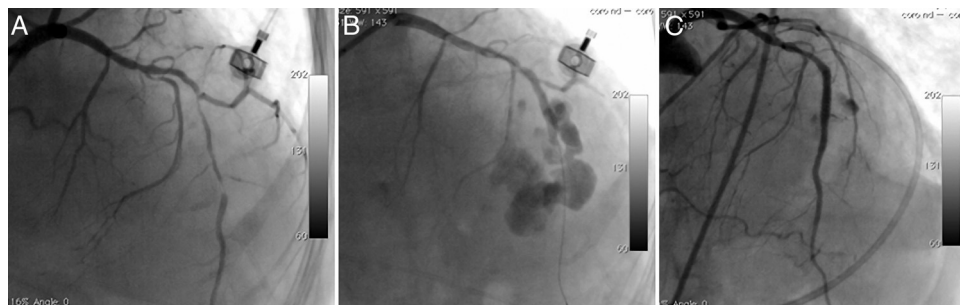


Figure 4 Long, thin, angulated and eccentric critical sequential lesions with thrombus in the mid to distal portion of the left anterior descending coronary artery (A); type IV coronary rupture showing prominent contrast flow into the left ventricle (B); control angiogram showing no extravasation around the target area after covered stent implantation (C).

not.^{4,19–21} This may be a selection bias, since these agents are generally used in more complicated conditions, but another possible explanation is that they may unmask a minimal vessel tear and convert it to overt perforation.²¹

Therapeutic strategies include prolonged balloon inflation, covered stents, reversal of anticoagulation, embolization of the distal vessel and surgery, the choice depending on the site and severity of the perforation, the patient's hemodynamic status and the equipment available in the catheterization laboratory.⁸ Echocardiography should be performed as soon as a perforation is identified. If pericardial hemorrhage or hemodynamic collapse occur pericardiocentesis should be performed immediately with multiple side holes for continuous aspiration, after which the drain should be kept in place for 6–24 hours and reaccumulation should be monitored with echocardiography.¹² Administration of fluids is recommended. A balloon should immediately be placed with inflations lasting up to 5–10 minutes to block extravasation. If the perforation cannot be sealed, repeated inflations should be made. Distal ischemia being a concern, perfusion balloons can be used without blocking distal blood flow. Reversal of anticoagulation can be achieved with protamine. As previously shown, the use of protamine is safe and does not predispose to stent thrombosis.^{14,22} However, diabetic patients on protamine containing insulin and patients with fish allergy are at increased risk for protamine reactions. GP IIb/IIIa inhibitors should also be discontinued and platelet transfusions should be used if needed.

Deployment of a covered stent is another therapeutic approach, especially with a large tear involving a proximal or mid coronary artery. Autologous vein-covered stents have been used successfully in the past,^{23,24} but this technique is time-consuming and requires expertise. Polytetrafluoroethylene (PTFE) is an inert and biocompatible polymer composed of carbon chains saturated with fluorine and in contrast to vein-covered stents, PTFE-covered stents are easy and rapid to deploy. However, due to the high profile and poor flexibility of these stents, it is often difficult to deliver them to the target site, especially when the vessel is heavily calcified and tortuous.²⁵ The use of IVUS to ensure correct stent implantation and final high-pressure balloon inflation may improve the outcome.²⁶ Pericardium-covered stents with greater flexibility are an alternative treatment, although experience is limited.²⁷ Stent thrombosis and in-stent restenosis are major concerns with covered stents, as is side branch occlusion.^{19,25} Although data are scarce, prasugrel, due to its lack of intrinsic resistance, can be considered the thienopyridine of choice for stent thrombosis.²⁸ Another major drawback, the time elapsed between deflation of the sealing balloon and the final delivery of the covered stent to the lesion site, can be overcome by a dual catheter technique.²⁹

Alternative therapies used in selected cases include coil embolization, thrombogenic particles including polyvinyl alcohol, gelfoam, thrombin, embolic agents like N-butyl cyanoacrylate glue, and autologous blood clot.^{30,31} Although potentially useful in emergency situations, these agents carry a risk of loss of the vessel lumen and subsequent infarction. Vessel occlusion techniques should therefore be used as a last resort for the treatment of distal perforations, in which the potential for myocardial injury is limited.³⁰

If a large perforation causes severe ischemia or hemodynamic deterioration or cannot be sealed with the available techniques, emergency surgery is indicated. Surgical intervention may be life-saving, but, since these patients have more severe perforations, it is associated with higher morbidity and mortality and worse outcome. Earlier surgical referral should be considered in this context when dealing with high-grade perforations.⁶

Conclusions

CAP is a rare but feared complication in the catheterization laboratory. PCI in calcified or tortuous vessels or in chronic total occlusions or complex lesions increases the risk of CAP. Choosing appropriate therapy may be life-saving.

Ethical disclosures

Protection of human and animal subjects. The authors declare that no experiments were performed on humans or animals for this study.

Confidentiality of data. The authors declare that they have followed the protocols of their work center on the publication of patient data and that all the patients included in the study received sufficient information and gave their written informed consent to participate in the study.

Right to privacy and informed consent. The authors have obtained the written informed consent of the patients or subjects mentioned in the article. The corresponding author is in possession of this document.

Conflicts of interest

The authors have no conflicts of interest to declare.

References

1. Ellis SG, Ajluni S, Arnold AZ, Popma JJ, Bittl JA, Eigler NL, et al. Increased coronary perforation in the new device era. Incidence, classification, management and outcome. *Circulation*. 1994;90:2725–30.
2. Bittl JA, Ryan Jr TJ, Keaney Jr JF, Tchong JE, Ellis SG, Isner JM, et al. Coronary artery perforation during excimer laser coronary angioplasty. The percutaneous Excimer Laser Coronary Angioplasty Registry. *J Am Coll Cardiol*. 1993 Apr;21(5):1158–65.
3. Gruberg L, Pinnow E, Flood R, Bonnet Y, Tebeica M, Waksman R, et al. Incidence, management and outcome of coronary artery perforation during percutaneous coronary intervention. *Am J Cardiol*. 2000;86:680–2.
4. Doll JA, Nikolsky E, Stone GW, Mehran R, Lincoff AM, Caixeta A, et al. Outcomes of patients with coronary artery perforation complicating percutaneous coronary intervention and correlations with the type of adjunctive antithrombotic therapy: pooled analysis from REPLACE-2, ACUITY, and HORIZONS-AMI trials. *J Interv Cardiol*. 2009;22:453–9.
5. Shimony A, Zahger D, Van Straten M, Shalev A, Gilutz H, Ilia R, et al. Incidence, risk factors, management and outcomes of coronary artery perforation during percutaneous coronary intervention. *Am J Cardiol*. 2009;104:1674–7.
6. Mark Gunning, Martyn Thomas Coronary artery perforation. Chapter 32. In: Simon Redwood, Nick Curzen, Martyn Thomas.

- Oxford Textbook of Interventional Cardiology. Oxford University Press, USA, 2010 New York; Toronto.
7. Fasseas P, Orford JL, Panetta CJ, Bell MR, Denktas AE, Lennon RJ, et al. Incidence, correlates, management, and clinical outcome of coronary perforation: analysis of 16,298 procedures. *Am Heart J*. 2004 Jan;147(1):140–5.
 8. Shimony A, Joseph L, Mottillo S, Eisenberg MJ. Coronary artery perforation during percutaneous coronary intervention: a systematic review and meta-analysis. *Can J Cardiol*. 2011 Nov;27(6):843–50.
 9. Ajluni SC, Glazier S, Blankenship L, O'Neill WW, Safian RD. Perforations after percutaneous coronary interventions: clinical, angiographic, and therapeutic observations. *Cathet Cardiovasc Diagn*. 1994 Jul;32(3):206–12.
 10. Muller O, Windecker S, Cuisset T, et al. Management of two major complications in the cardiac catheterisation laboratory: the no-reflow phenomenon and coronary perforations. *EuroIntervention*. 2008;4:181–92.
 11. Fukutomi T, Suzuki T, Popma JJ, Hosokawa H, Yokoya K, Inada T, et al. Early and late clinical outcomes following coronary perforation in patients undergoing percutaneous coronary intervention. *Circ J*. 2002 Apr;66(4):349–56.
 12. Nair P, Roguin A. Coronary perforations. *EuroIntervention*. 2006 Nov;2(3):363–70.
 13. Maruo T, Yasuda S, Miyazaki S. Delayed appearance of coronary artery perforation following cutting balloon angioplasty. *Catheter Cardiovasc Interv*. 2002;57:529–31.
 14. Witzke CF, Martin-Herrero F, Clarke SC, Pomerantzev E, Palacios IF. The changing pattern of coronary perforation during percutaneous coronary intervention in the new device era. *J Invasive Cardiol*. 2004 Jun;16(6):257–301.
 15. Kiernan TJ, Yan BP, Ruggiero N, Eisenberg JD, Bernal J, Cubeddu RJ, et al. Coronary artery perforations in the contemporary interventional era. *J Interv Cardiol*. 2009 Aug;22(4):350–3.
 16. Javaid A, Buch AN, Satler LF, Kent KM, Suddath WO, Lindsay Jr J, et al. Management and outcomes of coronary artery perforation during percutaneous coronary intervention. *Am J Cardiol*. 2006 Oct 1;98(7):911–4.
 17. Al-Mukhaini M, Panduranga P, Sulaiman K, Riyami AA, Deeb M, Riyami MB. Coronary perforation and covered stents: an update and review. *Heart Views*. 2011 Apr;12(2):63–70.
 18. Dippel EJ, Kereiakes DJ, Tramuta DA, Broderick TM, Shimshak TM, Roth EM, et al. Coronary perforation during percutaneous coronary intervention in the era of abciximab platelet glycoprotein IIb/IIIa blockade: an algorithm for percutaneous management. *Catheter Cardiovasc Interv*. 2001 Mar;52(3):279–86.
 19. Al-Lamee R, Ielasi A, Latib A, Godino C, Ferraro M, Mussardo M, et al. Incidence, predictors, management, immediate and long-term outcomes following grade III coronary perforation. *JACC Cardiovasc Interv*. 2011 Jan;4(1):87–95.
 20. Stankovic G, Orlic D, Corvaja N, Airolidi F, Chieffo A, Spanos V, et al. Incidence, predictors, in-hospital, and late outcomes of coronary artery perforations. *Am J Cardiol*. 2004 Jan 15;93(2):213–6.
 21. Colombo A, Stankovic G. Coronary perforations: old screenplay, new actors! *J Invasive Cardiol*. 2004 Jun;16(6):302–3.
 22. Briguori C, Di Mario C, De Gregorio J, Sheiban I, Vaghetti M, Colombo A. Administration of protamine after coronary stent deployment. *Am Heart J*. 1999 Jul;138 1 Pt 1:64–8.
 23. Colombo A, Itoh A, Di Mario C, Maiello L, Arena V, Blengino S, et al. Successful closure of a coronary vessel rupture with a vein graft stent: case report. *Cathet Cardiovasc Diagn*. 1996;38:172–4.
 24. Caputo RP, Amin N, Marvasti M, Wagner S, Levy C, Giambartolomei A. Successful treatment of a saphenous vein graft perforation with an autologous vein-covered stent. *Cathet Cardiovasc Interv*. 1999;48:382–6.
 25. Romaguera R, Waksman R. Covered stents for coronary perforations: is there enough evidence? *Catheter Cardiovasc Interv*. 2011 Aug 1;78(2):246–53.
 26. Briguori C, Nishida T, Anzuini A, Di Mario C, Grube E, Colombo A. Emergency polytetrafluoroethylene-covered stent implantation to treat coronary ruptures. *Circulation*. 2000;102:3028–31.
 27. Jokhi PP, McKenzie DB, O'Kane P. Use of a novel pericardial covered stent to seal an iatrogenic coronary perforation. *J Invasive Cardiol*. 2009;21:E187–90.
 28. Eeckhout E, De Palma R. Coronary perforation: an inconvenient complication. *JACC Cardiovasc Interv*. 2011 Jan;4(1):96–7.
 29. Ben-Gal Y, Weisz G, Collins MB, Genereux P, Dangas GD, Teirstein PS, Singh VP, Rabbani LE, Kodali SK, Sherman W, Leon MB, Moses JW. Dual catheter technique for the treatment of severe coronary artery perforations. *Catheter Cardiovasc Interv*. 2010;75:708–12.
 30. Pershad A, Yarkoni A, Biglari D. Management of distal coronary perforations. *J Invasive Cardiol*. 2008 Jun;20(6). E187-91. Review.
 31. Fischell TA, Korban EH, Lauer MA. Successful treatment of distal coronary guidewire-induced perforation with balloon catheter delivery of intracoronary thrombin. *Catheter Cardiovasc Interv*. 2003 Mar;58(3):370–4.