


# Journal Pre-proof

Silent expansion: A case report of a young adult with ascending aortic aneurysm

Carla Costa Lígia Mendes Márcio Madeira



PII: S0870-2551(25)00286-0

DOI: <https://doi.org/doi:10.1016/j.repc.2025.03.009>

Reference: REPC 2482

To appear in: *Revista Portuguesa de Cardiologia*

Received Date: 16 January 2025

Accepted Date: 23 March 2025

Please cite this article as: Costa C, Mendes L, Madeira M, Silent expansion: A case report of a young adult with ascending aortic aneurysm, *Revista Portuguesa de Cardiologia* (2025), doi: <https://doi.org/10.1016/j.repc.2025.03.009>

This is a PDF file of an article that has undergone enhancements after acceptance, such as the addition of a cover page and metadata, and formatting for readability, but it is not yet the definitive version of record. This version will undergo additional copyediting, typesetting and review before it is published in its final form, but we are providing this version to give early visibility of the article. Please note that, during the production process, errors may be discovered which could affect the content, and all legal disclaimers that apply to the journal pertain.

© 2025 Published by Elsevier España, S.L.U. on behalf of Sociedade Portuguesa de Cardiologia.

**Title**

Silent expansion: A case report of a young adult with ascending aortic aneurysm  
Expansão silenciosa: o caso de um jovem adulto com aneurisma da aorta ascendente

**Authors:**

Carla Costa<sup>1\*</sup>, Lígia Mendes<sup>2</sup>, Márcio Madeira<sup>3</sup>

<sup>1</sup>Intensive Care Medicine Department, Unidade Local de Saúde Loures-Odivelas, Portugal

<sup>2</sup>Cardiology Department, Hospital da Luz de Setúbal, Setúbal, Portugal

<sup>3</sup>Cardiothoracic Surgery Department, Unidade Local de Saúde Lisboa Ocidental; Lisboa, Portugal

\*Corresponding author:

E-mail address: carla.costa.01@hotmail.com

**Case report**

A 29-year-old male, previously healthy, presented to the emergency department (ED) with complaints of fatigue and chest pain following a tennis match, without any other associated symptoms. His clinical examination was unremarkable. Laboratory investigations revealed a hemoglobin level of 13.5 g/dL, a D-dimer of 0.66 mg/L, CK-MB <2 ng/mL, troponin <0.01 ng/L, and C-reactive protein of 2.20 mg/dL. An initial electrocardiogram (ECG) was normal. The patient was discharged with analgesics and referred to cardiology for follow-up.

One week later, he returned to the ED with progressively worsening chest pain over the preceding 24 hours, which radiated to his back. Laboratory findings remained consistent with the initial presentation. A transthoracic echocardiogram revealed marked enlargement of the ascending aorta and aortic arch, measuring approximately 8 cm in diameter, tricuspid aortic valve with mild regurgitation and preserved ejection fraction. Subsequent chest computed tomography confirmed a large ascending aortic aneurysm (AAA) with an expanded aortic root, measuring 85x81 mm (Figure 1). A subacute hematoma was observed without evidence of dissection, along with a pericardial effusion measuring 18 mm in thickness. There was no known family history of aortic disease or other hereditary cardiovascular conditions.

The patient was transferred to a specialized cardiothoracic center, where he underwent successful replacement of the ascending aorta and aortic arch using a conduit (Figure 2). The surgery was uneventful. Intraoperatively, an aortic dissection extended to the aortic arch was identified. Histopathological examination revealed pathological accumulation of extracellular matrix components, leading to degeneration of the elastic fibers in the aortic wall. Genetic testing was negative for Marfan syndrome (*FBN1* mutation), Loeys-Dietz syndrome (*TGFBR1/2* mutations), and vascular Ehlers-Danlos syndrome (*COL3A1* mutation).

**Key messages**

An AAA is an abnormal dilation of the ascending aorta, typically exceeding 1.5 times its normal diameter. While often linked to hypertension, smoking, and atherosclerosis in older adults, it can also affect young individuals due to structural aortic abnormalities [1]. Histopathology frequently shows cystic medial degeneration, marked by smooth muscle loss, elastic fiber fragmentation, and extracellular matrix accumulation, a hallmark of connective tissue disorders [2]. However, when genetic testing is unavailable or inconclusive, the underlying cause may remain undetermined [3]. AAAs are often asymptomatic until they reach a critical size or complications arise, such as rupture or dissection. Early detection is frequently incidental, typically during imaging studies performed for unrelated reasons [3].

Management strategies depend on the aneurysm's size, growth rate, and associated risks. Surgical intervention, either through open repair or endovascular techniques, is reserved for larger aneurysms, those demonstrating rapid expansion or complications.

#### Funding

There was no external funding supporting this paperwork.

#### Conflicts of interest

The authors have no conflicts of interest to declare.

#### Ethics in publishing

1. Does your research involve experimentation on animals?:

No

2. Does your study include human subjects?:

No

3. Does your study include a clinical trial?:

No

4. Are all data shown in the figures and tables also shown in the text of the Results section and discussed in the Conclusions?:

Yes

## References

1. Isselbacher, E. M. (2005). Thoracic and abdominal aortic aneurysms. *Circulation*, 111(6), 816–828. doi:10.1161/01.CIR.0000154569.08857.7A
2. Humphrey, J. D., & Schwartz, M. A. (2020). Biomechanical and biochemical remodeling in the pathogenesis of aortic aneurysms. *JACC Basic to Translational Science*, 5(10), 1107–1122. doi:10.1016/j.jacbts.2020.09.008
3. Hiratzka, L. F., et al. (2010). 2010 ACCF/AHA/AATS/ACR/ASA/SCA/SCAI/SIR/STS/SVM guidelines for the diagnosis and management of patients with thoracic aortic disease. *Circulation*, 121(13), e266–e369. doi:10.1161/CIR.0b013e3181d4739e

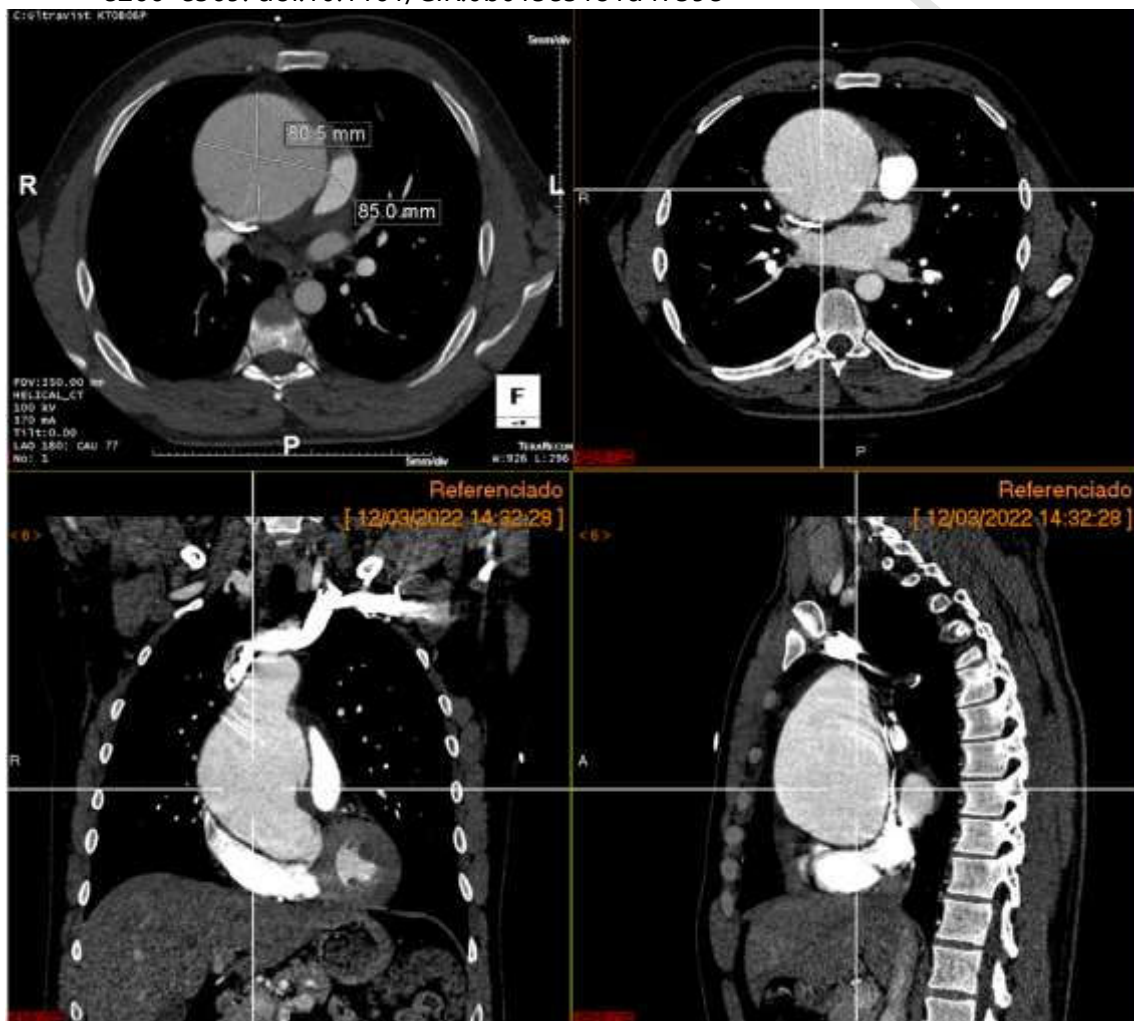


Figure 1: Chest computed tomography showing enlargement of the ascending aortic artery.

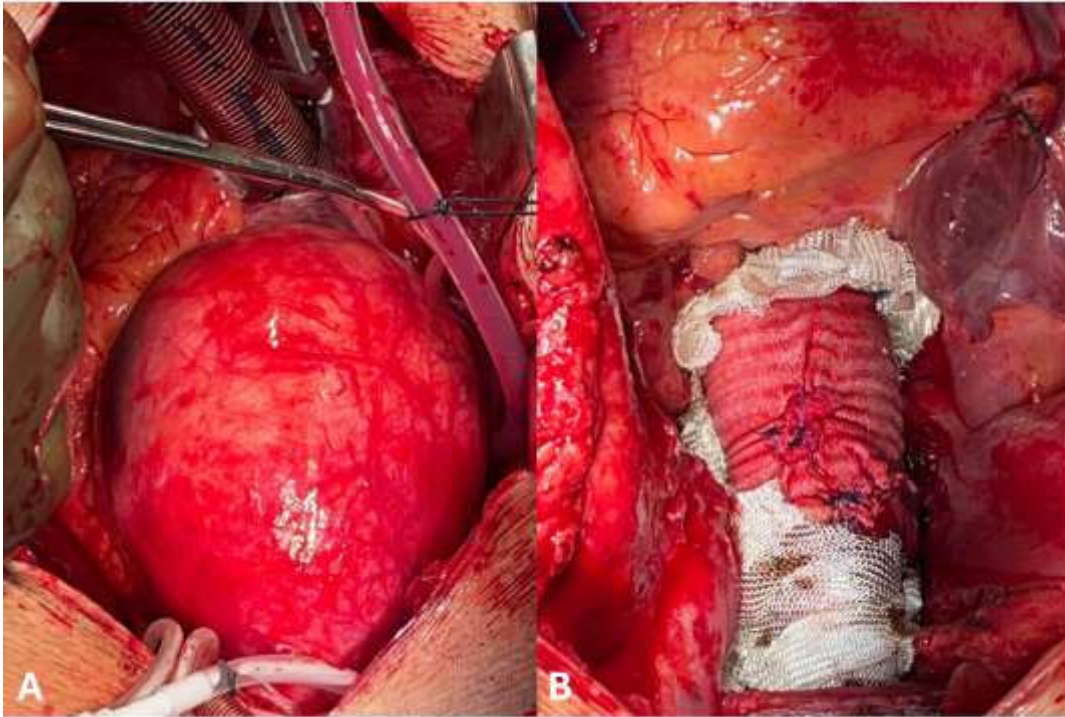


Figure 2: Macroscopic view at the start of surgery (A) and post replacement with a conduit (B).