



## IMAGE IN CARDIOLOGY

## Sinus Node Syndrome in a critical COVID-19 patient

## Doença do nódulo sinusal num doente crítico com COVID-19

Juliana Elices-Teja<sup>a</sup>, Álvaro Bueno-Sacristán<sup>b</sup>, Olga Durán-Bobin<sup>a</sup>,  
 Ana María Ferreiro-González<sup>b</sup>, Carlos Gonzalez-Juanatey<sup>a,\*</sup>

<sup>a</sup> Cardiology Department, Hospital Universitario Lucus Augusti, Lugo, Spain

<sup>b</sup> Intensive Care Unit, Hospital Universitario Lucus Augusti, Lugo, Spain

Received 30 June 2020; accepted 13 September 2020

Available online 14 September 2021



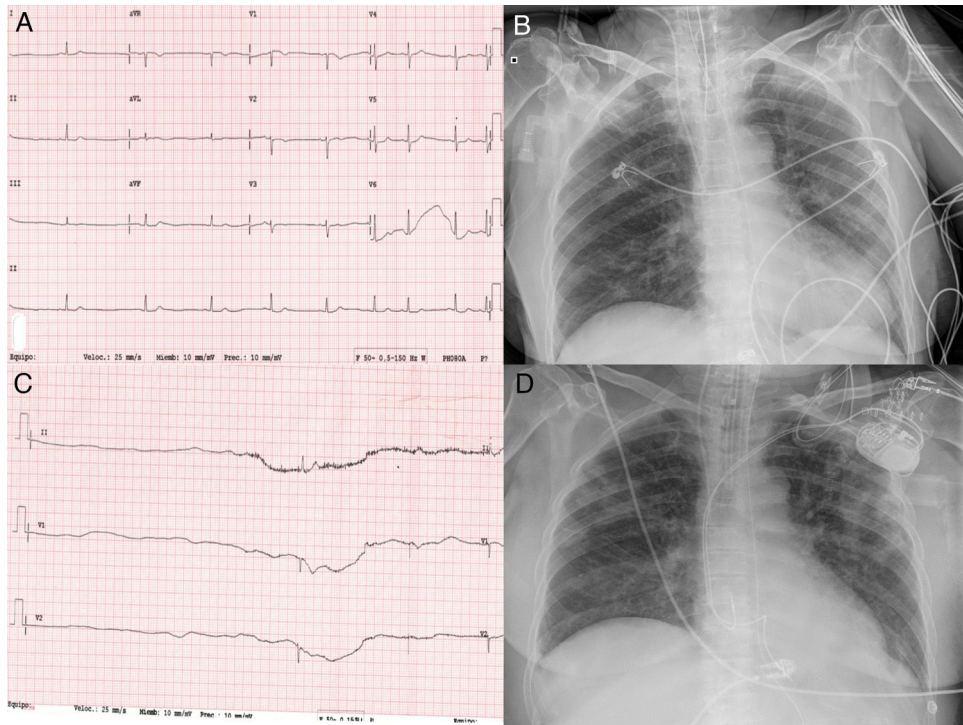
A 75 year-old woman with no previous remarkable clinical history was admitted to hospital with diagnosed COVID-19 diffuse bilateral pneumonia. She was treated with hydroxychloroquine, lopinavir-ritonavir, azithromycin, and methylprednisolone. On day 10 of the hospital stay, she was intubated due to severe hypoxemia. She showed a significant increase of interleukin-6 (105 pg/ml) with normal N-terminal pro-B-type peptide and high sensitive Troponin I. Interferon beta1-b and tocilizumab were prescribed. On day 33 of the hospital stay, the patient suddenly presented sinus bradycardia and multiple sinus arrest (pauses >10 seconds), [Figure 1](#). An echocardiogram was performed without

pathological findings, and a dual chamber pacemaker was implanted without complications. The clinical course was good, and she was discharged from the intensive care unit on day 55 after admission.

Cardiovascular (CV) complications are common in COVID19 patients, including arrhythmias, myocarditis, heart failure and acute coronary syndromes. The systemic inflammatory response to infection could be involved in COVID19-induced CV complications. The possible etiological mechanisms of sinus node dysfunction could be multifactorial, including severe hypoxia, exaggerated response to medication and inflammatory status. Cytokine storm

\* Corresponding author.

E-mail address: [carlos.gonzalez.juanatey@sergas.es](mailto:carlos.gonzalez.juanatey@sergas.es)  
 (C. Gonzalez-Juanatey).



**Figure 1** (A) Electrocardiogram showing sinus bradycardia and (B) sinus arrest with a pause >6 seconds. (C and D) Chest x-ray showing bilateral pulmonary infiltrates predominantly peripheral, before and after pacemaker implantation.

with high levels of pro-inflammatory cytokines could directly damage cardiac pacemaker cells contributing to the sinoatrial node dysfunction. To our knowledge this is the first case of sinus node syndrome that required a pacemaker implantation in a critical COVID-19 patient.

### Conflicts of interest

The authors have no conflicts of interest to declare.