



IMAGE IN CARDIOLOGY

**The biggest right atria in the world**

**A maior aurícula direita do mundo**



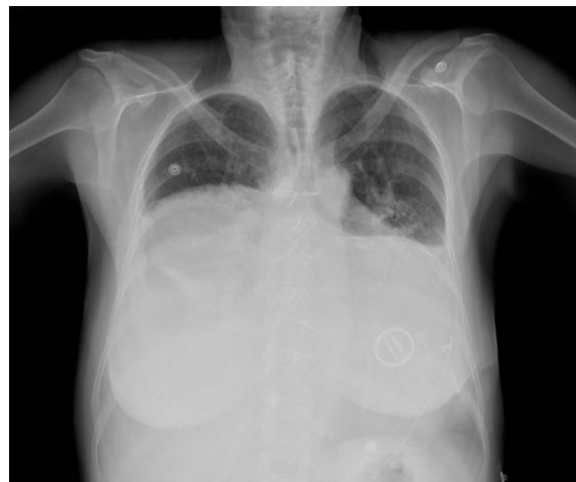Edison Muñoz Ortiz<sup>a,b,\*</sup>, Jairo Alfonso Gándara Ricardo<sup>a,b</sup>, Edwin Arévalo Guerrero<sup>a</sup>

<sup>a</sup> *Unidad Funcional Cardiopulmonar y Vascular Periférico, Hospital Universitario San Vicente Fundación, Medellín, Colombia*

<sup>b</sup> *Sección Cardiología, Departamento de Medicina Interna, Universidad de Antioquia, Medellín, Colombia*

Received 26 July 2020; accepted 13 September 2020

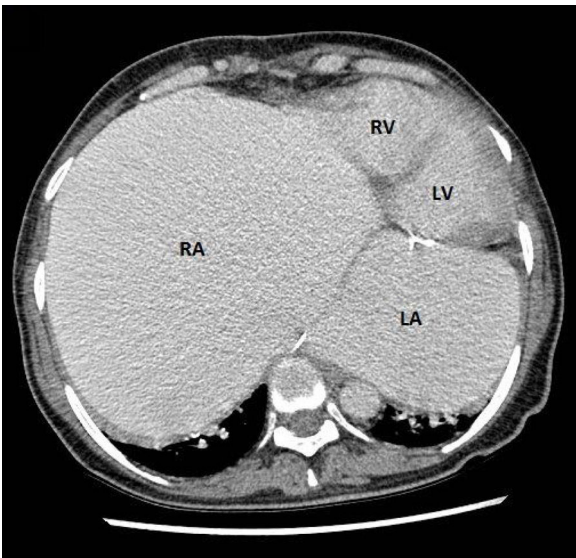
A 55-year-old woman arrived at the emergency room with dyspnea and generalized edema. The patient had as relevant medical history, a mechanical mitral valve, severe tricuspid regurgitation, pericardiectomy apparently due to recurrent pericardial effusion, atrial fibrillation and a pacemaker for complete atrioventricular block. Physical examination revealed signs of right-sided heart failure and tricuspid regurgitation. The chest X-ray (Figure 1), echocardiography and computed tomography (Figure 2) revealed a giant right atrium (18 cm×15.3 cm×16.3 cm) and giant left atrium (13.1 cm×9.6 cm×9.1 cm). Right and left ventricles had normal size and function. She also had severe tricuspid regurgitation and a normally functioning mitral prosthesis. The atria were so large that they were causing pulmonary restriction and dyspnea that was difficult to manage. The patient presented progressive deterioration during hospitalization and despite heart failure treatment she died.



**Figure 1** Chest X-ray with giant cardiac silhouette, sternal suture and mechanical mitral valve.

\* Corresponding author.

E-mail address: [edison.munoz@sanvicentefundacion.com](mailto:edison.munoz@sanvicentefundacion.com)  
 (E. Muñoz Ortiz).



**Figure 2** Computed tomography showing giant right and left atria, the right atrium being much more dilated. The ventricles are normal in size and function. LA: left atrium; LV: left ventricle; RA: right atrium; RV: right ventricle.

## Funding

Primary funders: Hospital Universitario San Vicente Fundación and Universidad de Antioquia.

## Conflicts of interest

The authors have no conflicts of interest to declare.