

## IMAGE IN CARDIOLOGY

# Usefulness of cardiac MRI in the early diagnosis of endomyocardial fibrosis

## Utilidade da ressonância magnética cardíaca no diagnóstico precoce da endomiocardiofibrose

Diego León<sup>a,\*</sup>, María Martín<sup>a</sup>, Cecilia Corros<sup>a</sup>, Elena Santamarta<sup>b</sup>, Serafín Costilla<sup>b</sup>, José L. Lambert<sup>a</sup>

<sup>a</sup> Cardiology Department, Hospital Universitario Central de Asturias, Oviedo, Spain

<sup>b</sup> Radiology Department, Hospital Universitario Central de Asturias, Oviedo, Spain

Received 4 September 2011; accepted 20 December 2011

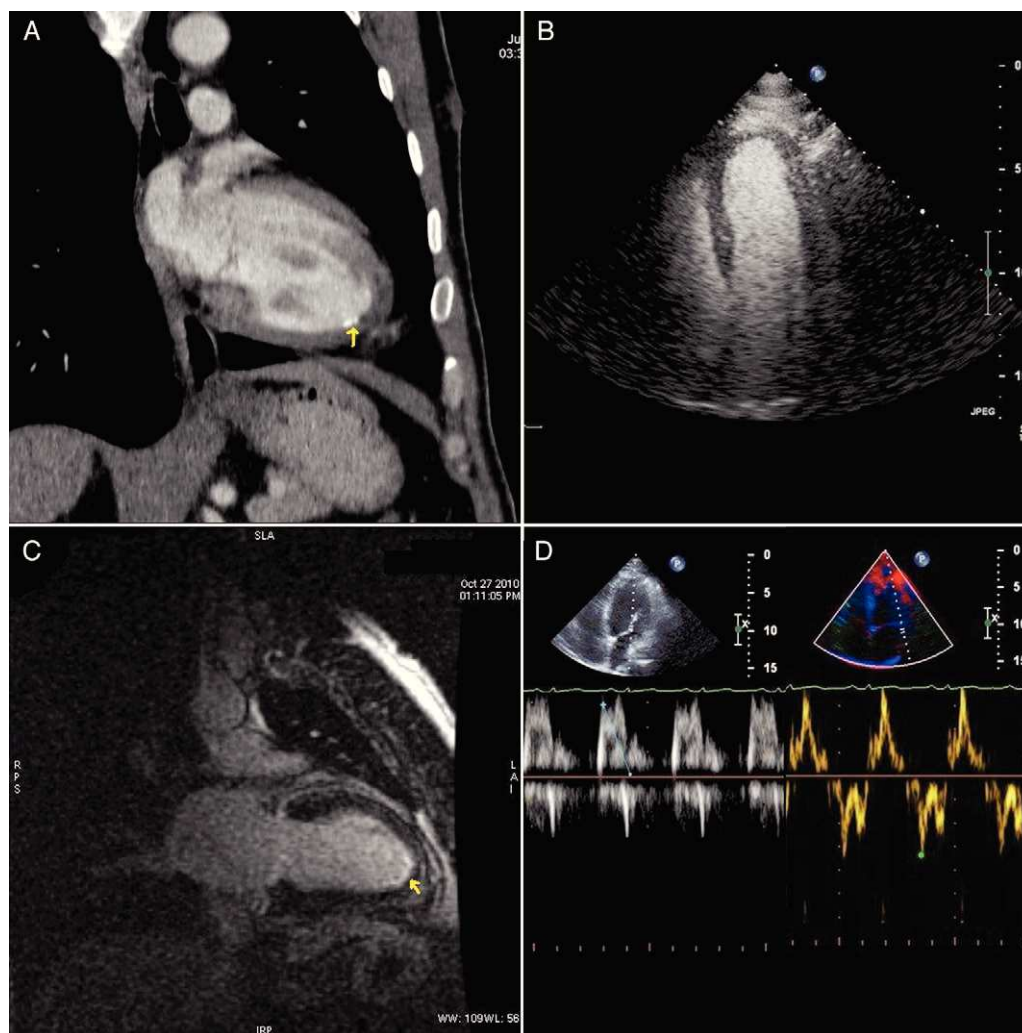
Endomyocardial fibrosis (EF) is characterized by marked endocardial thickening of the apex and subvalvular apparatus of one or both ventricles. It is considered a primary and chronic form of restrictive cardiomyopathy (the acute form is Löffler's disease) and is associated with inflammation and hypereosinophilia secondary to chronic processes such as parasite infection or autoimmune disease.

We describe the case of a 38-year-old Guinean man who was admitted to the Internal Medicine department for left upper quadrant pain. He had a previous history of malaria. Physical exam revealed a 4-cm hepatomegaly

with tenderness in the epigastrium and hypochondrium without signs of heart failure. The hemogram showed marked eosinophilia ( $29\,500/\text{mm}^3$ ) and *loa loa* microfilariae were identified in the blood circulation. Thoraco-abdominal CT confirmed hepato- and splenomegaly and showed mild calcification in the left ventricular apex (Figure 1A, arrow). Given the suspicion of EF, the patient was referred for echocardiographic assessment (Figure 1B). Contrast echo revealed no suspicion of restrictive cardiomyopathy, the left ventricle was normal in size and systolic and diastolic function were both normal, with normal filling pressures

\* Corresponding author.

E-mail address: [diegoleon2000@gmail.com](mailto:diegoleon2000@gmail.com) (D. León).



**Figure 1** Imaging studies performed to establish diagnosis of endomyocardial fibrosis: Thoraco-abdominal CT (A), transthoracic contrast echo (B, C), and cardiac MRI (D).

(Figure 1C). Finally, on cardiac MRI subendocardial late gadolinium hyperenhancement was observed in the left ventricular apex (Figure 1D, arrow), reflecting myocardial fibrosis. The patient's clinical context supports the diagnosis of an initial stage of EF. Cardiac MRI is a very useful tool for the diagnosis of EF as it enables characterization

and quantification of fibrous tissue, which has prognostic value.

### Conflicts of interest

The authors have no conflicts of interest to declare.