

IMAGE IN CARDIOLOGY

Echocardiographic findings of iatrogenic septal defect during TA-AVI

Achados ecocardiograficos de comunicação interventricular iatrogênica durante TA-AVI

Paolo Giuseppe Pino, Amedeo Pergolini, Giordano Zampi*

Department of Cardiovascular Science, "S. Camillo-Forlanini" Hospital, Rome, Italy

Received 5 August 2011; accepted 16 September 2011

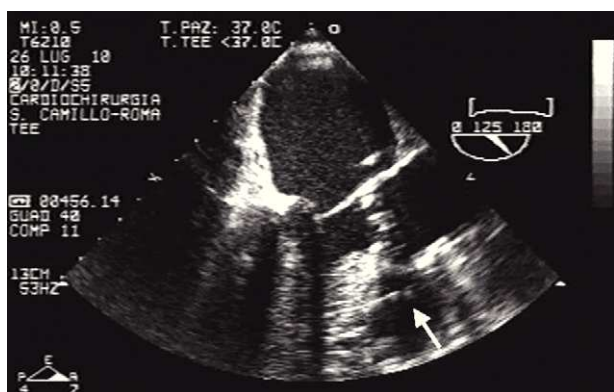


Figure 1 Intraoperative transesophageal echocardiography (TEE): valvuloplasty catheter impinging on the interventricular septum (white arrow).

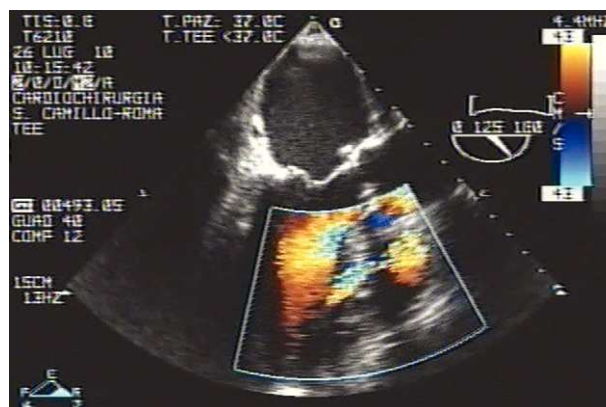

Figure 2 Intraoperative TEE: a clear left-to-right shunt was detected on color Doppler.

Peri-procedural complications may occur in transapical aortic valve implantation (TA-AVI).

On intraoperative transesophageal echocardiography, after apical puncture, the valvuloplasty catheter impinged

on the interventricular septum (Fig. 1, Video 1). When the catheter was pulled back, an iatrogenic ventricular septal defect (VSD) with a clear left-to-right shunt was detected (Fig. 2, Video 2). TA-AVI was then performed without any other complications. One year later the patient was asymptomatic and in good clinical condition. The VSD

* Corresponding author.

E-mail address: giordano.zampi@alice.it (G. Zampi).

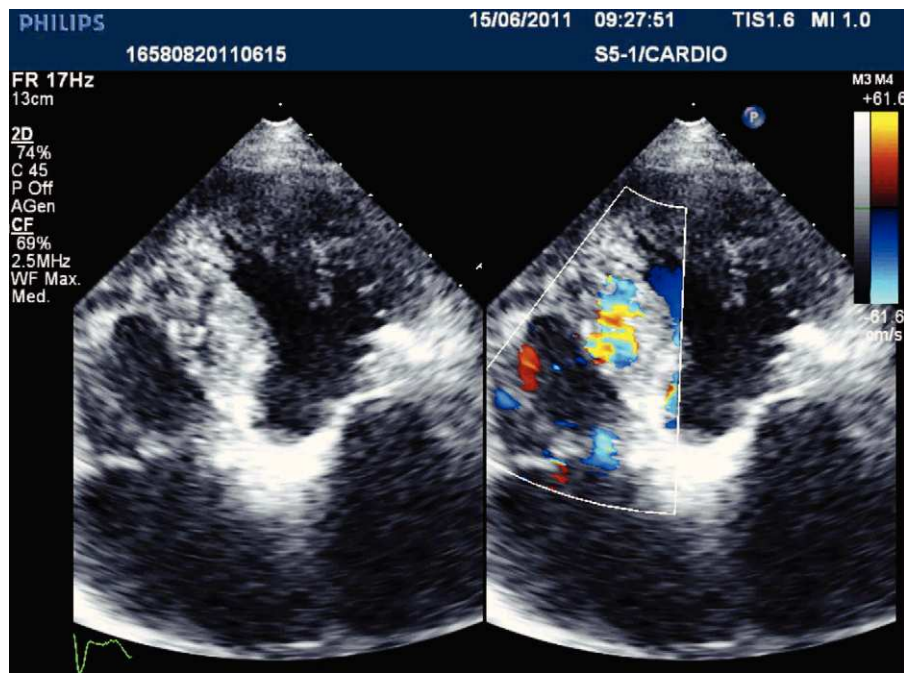


Figure 3 Follow-up TTE: the VSD was still clear and patent.

was confirmed by transthoracic echocardiography (Fig. 3, Video 3), with a Qp/Qs of 1.2.

Conflicts of interest

The authors have no conflicts of interest to declare.

Appendix A. SUPPLEMENTARY MATERIAL

Supplementary material associated with this article can be found in the online version available at [doi:10.1016/j.repc.2011.12.007](https://doi.org/10.1016/j.repc.2011.12.007).