

IMAGE IN CARDIOLOGY

Looking in the mirror: An unusual optical coherence tomography image



Olhando para o espelho: uma tomografia de coerência ótica com uma imagem invulgar

Patrícia Marques-Alves^{a,b,*}, Luís Leite^{a,b}, Vítor Matos^a, Lino Gonçalves^{a,b}

^a Department of Cardiology, Centro Hospitalar e Universitário de Coimbra, Coimbra, Portugal

^b Faculty of Medicine, University of Coimbra, Coimbra, Portugal

Received 10 September 2019; accepted 19 September 2019

A 75-year-old male underwent primary angioplasty of a sub-occlusive proximal to medial left anterior descending artery (LAD) stenosis, involving the origin of the first diagonal (D1). A provisional stenting technique was used, with two guidewires in the distal LAD and D1 and implantation of 3 mm×30 mm and 2.75 mm×28 mm drug-eluting stents (DES)

in the LAD. Withdrawal of the jailed D1 guidewire caused a deep intubation of the guide catheter into the LAD. The subsequent angiogram was notable for a suspicious haziness proximal to the stents (Figure 1A, arrow). We decided to perform optical coherence tomography (OCT) of the LAD. However, the catheter did not pass further than the proximal

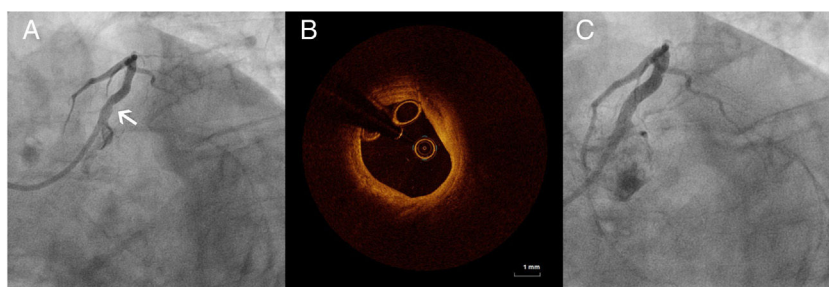


Figure 1 (A) Angiography showing a suspicious haziness proximal to the stents (arrow); (B) optical coherence tomography image of the proximal left anterior descending artery (proximal to the stent), with a suspicious circular image; (C) final angiographic result, after angioplasty with a 3.5 mm×18 mm drug-eluting stent proximal to the previous stents.

* Corresponding author.
E-mail address: pat.marques.alves@gmail.com
(P. Marques-Alves).

segment, showing a conspicuous circular image (Figure 1B). Meanwhile, the intravascular ultrasound catheter was able to progress and did not show the image, only malapposed struts. Angioplasty proximal to the previous stents was performed with implantation of a 3.5 mm×18 mm DES, with a good final angiographic result (Figure 1C). In subsequent OCT images the circular image had disappeared.

We postulate that the intubation of the guide catheter during retrieval of the jailed guidewire damaged the proximal stent struts. Thus, the circular OCT image was of the OCT catheter itself, which was folded by attempts to pass

the catheter through the damaged stent. Our case illustrates an unusual image that can lead to uncertainties during OCT-guided angioplasty. The report of this peculiarity could help the interpretation of doubtful OCT images obtained in daily practice in the cath lab.

Conflicts of interest

The authors have no conflicts of interest to declare.