



## IMAGE IN CARDIOLOGY

# A rare case of isolated anomalous origin of the left pulmonary artery



## Um caso raro e isolado de origem anómala do ramo esquerdo da artéria pulmonar

Lisete Lopes\*, Helena Andrade, António Pires

*Hospital Pediatrico de Coimbra, Serviço de Cardiologia Pediátrica, Coimbra, Portugal*

Received 1 June 2019; accepted 22 February 2020

Anomalous origin of a pulmonary artery branch from the aorta is a rare congenital cardiac malformation. We report the case of a neonate with this rare entity.

### Case study

A full-term asymptomatic female neonate with a systolic murmur was referred to our department for a cardiology review.

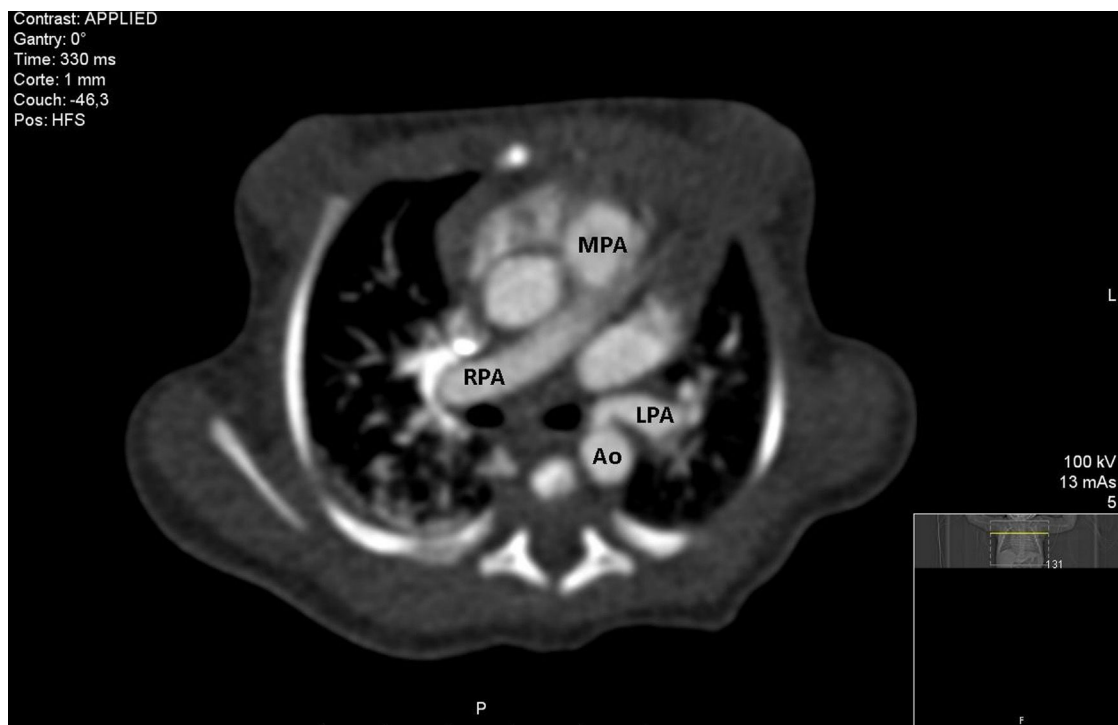
The echocardiogram failed to show the left pulmonary artery branch. The remaining examination was normal.

For clarification, a computed tomography angiogram was performed. It showed the left pulmonary artery branch arising from the anterior aspect of the proximal descending thoracic aorta (Figures 1 and 2), 13 mm below the area from which the left subclavian artery arises. A diagnosis of anomalous origin of the left pulmonary artery was made.

To quantify pulmonary pressure, the patient underwent cardiac catheterization (Figures 3 and 4) at one year of age, which excluded pulmonary arterial hypertension.

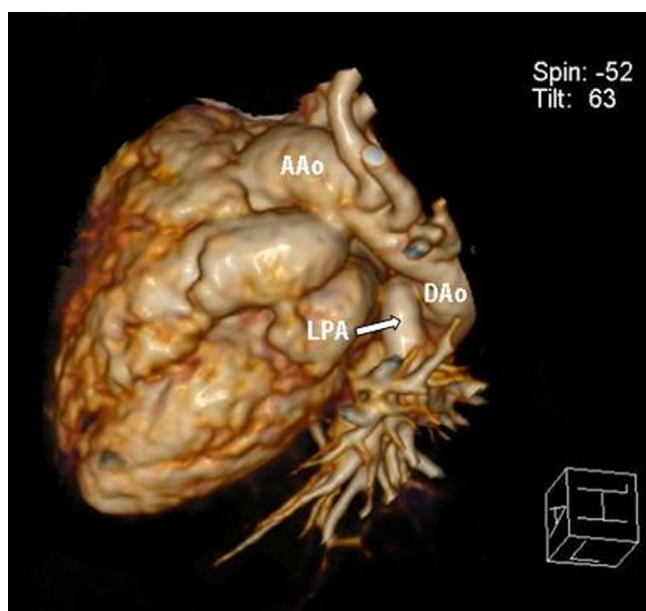
\* Corresponding author.

E-mail address: [lisete.pediatria@gmail.com](mailto:lisete.pediatria@gmail.com) (L. Lopes).



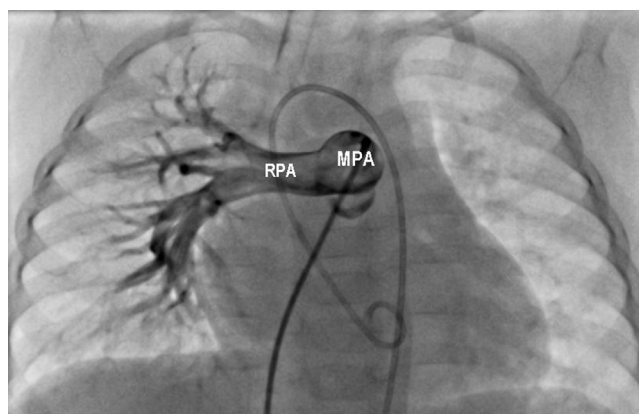
**Figure 1** Axial view computed tomography angiography showing the left pulmonary artery branch arising from the descending aorta.

Ao: aorta; LPA: left pulmonary artery; MPA: main pulmonary artery; RPA: right pulmonary artery.



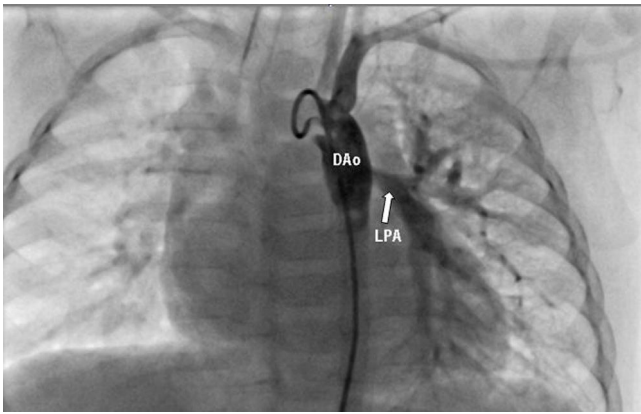
**Figure 2** Posterolateral view of three-dimensional computed tomography angiography reconstruction showing the left pulmonary artery branch arising from the anterior aspect of the proximal descending thoracic aorta.

AAo: ascending aorta; LPA: left pulmonary artery; DAo: descending aorta.



**Figure 3** Pulmonary angiography showing the absence of the left pulmonary artery branch.

RPA: right pulmonary artery; MPA: main pulmonary artery.



**Figure 4** Aortic angiography demonstrating anomalous origin of the left pulmonary artery from the descending thoracic aorta. LPA: left pulmonary artery; DAo: descending Aorta.

To the best of our knowledge, only two other cases with the same anatomical features have been reported in the literature. In the majority of cases, the right pulmonary artery branch is involved and usually arises from the posterolateral aspect of the ascending aorta.

### Conflicts of interest

The authors have no conflicts of interest to declare.