



SHORT COMMUNICATION

Invasive pulmonary aspergillosis in heart transplant recipients: Is mortality decreasing?



Eduardo Flores-Umanzor^{a,*}, Juan Betuel Ivey-Miranda^{a,b},
Margarida Pujol-Lopez^a, Pedro Cepas-Guillen^a, Andrea Fernandez-Valledor^a,
Guillen Caldentey^a, Marta Farrero^a, Ana García^a, Marta Sitges^a,
Felix Perez-Villa^a, Asunción Moreno^c, Rut Andrea^a, María A. Castel^a

^a University of Barcelona, Cardiology Department, Cardiovascular Institute, Barcelona, Spain

^b Instituto Mexicano del Seguro Social, Department of Cardiology, Cardiology Hospital, Mexico City, Mexico

^c University of Barcelona, Hospital Clinic, Infectious Disease Department, Barcelona, Spain

Received 7 March 2018; accepted 3 February 2019

KEYWORDS

Heart
transplantation;
Invasive pulmonary
aspergillosis;
Immunosuppression

Abstract

Introduction: Infection remains a major complication among heart transplant (HT) recipients, causing approximately 20% of deaths in the first year after transplantation. In this population, *Aspergillus* spp. can have various clinical presentations including invasive pulmonary aspergillosis (IPA), with high mortality (53-78%).

Objectives: To establish the characteristics of IPA infection in HT recipients and their outcomes in our center.

Methods: Among 328 HTs performed in our center between 1998 and 2016, we identified five cases of IPA. Patient medical records were examined and clinical variables were extracted.

Results: All cases were male, and mean age was 62 years. The most common indication for HT was non-ischemic dilated cardiomyopathy. Productive cough was reported as the main symptom. The radiological assessment was based on chest X-ray and chest computed tomography. The most commonly reported radiographic abnormality was multiple nodular opacities in both techniques. Bronchoscopy was performed in all patients and *Aspergillus fumigatus* was isolated in four cases on bronchoalveolar lavage culture. Treatment included amphotericin in four patients, subsequently changed to voriconazole in three, and posaconazole in one patient, with total treatment lasting an average of 12 months. Neutropenia was found in only one patient, renal failure was observed in two patients, and concurrent cytomegalovirus infection in three patients. All patients were alive after a mean follow-up of 18 months.

Conclusions: IPA is a potentially lethal complication after HT. Early diagnosis and prompt initiation of aggressive treatment are the cornerstone of better survival.

© 2019 Sociedade Portuguesa de Cardiologia. Published by Elsevier España, S.L.U. This is an open access article under the CC BY-NC-ND license (<http://creativecommons.org/licenses/by-nc-nd/4.0/>).

* Corresponding author.

E-mail address: ejfu0209@gmail.com (E. Flores-Umanzor).

PALAVRAS-CHAVE

Transplante cardíaco;
Aspergilose pulmonar
invasiva;
Imunossupressão

Aspergilose pulmonar invasiva nos recipientes de transplantes cardíacos: está a mortalidade a decrescer?

Resumo

Introdução: A infeção continua a ser uma complicação *major* nos recipientes para transplante cardíaco (TC), causando cerca de 20% de mortes no primeiro ano após o transplante. Nestes doentes, o *Aspergillus species* pode levar a várias apresentações clínicas incluindo a aspergilose pulmonar invasiva (API), com uma mortalidade elevada (53% a 78%).

Objetivos: Estabelecer as características da infeção por API nos recipientes para TC e os respetivos resultados no nosso serviço.

Métodos: Dos 328 transplantes cardíacos realizados no nosso centro entre 1998 e 2016, identificámos cinco casos de API. Foram examinados os registos dos doentes e foram identificadas variáveis clínicas.

Resultados: Em todos os casos os doentes eram do sexo masculino com idade média de 62 anos. A indicação mais comum para TC foi a miocardiopatia não isquémica dilatada. O principal sintoma foi tosse produtiva. A avaliação radiológica baseou-se na radiografia e na TAC torácicas. A alteração radiológica mais comum foi a densidade nodular múltipla em ambas as técnicas. A broncoscopia foi realizada em todos os doentes e o *Aspergillus fumigatus* foi isolado em quatro casos de cultura BAL. O tratamento incluiu anfotericina em quatro doentes com alteração subsequente para voriconazol em três doentes e posaconazol num doente, tendo o tratamento durado uma média de 12 meses. A neutropenia foi encontrada num doente apenas, a insuficiência renal foi observada em dois doentes e a infeção por CMV ocorreu em três doentes. Todos os doentes sobreviveram após seguimento de 18 meses.

Conclusão: A API representa uma complicação potencialmente mortal após o TC. Um diagnóstico precoce e a iniciação de um tratamento rapidamente agressivo constituem a pedra angular para uma melhor sobrevivência.

© 2019 Sociedade Portuguesa de Cardiologia. Publicado por Elsevier España, S.L.U. Este é um artigo Open Access sob uma licença CC BY-NC-ND (<http://creativecommons.org/licenses/by-nc-nd/4.0/>).

Introduction

Infection remains a major complication among transplant recipients, causing approximately 20% of deaths in the first year after transplantation, as well as being a major cause of long-term morbidity and mortality. In solid organs, such as cardiac transplantation, in which immunosuppressants are prescribed indefinitely, physicians and patients perpetually negotiate the delicate balance between the risks of graft rejection and infection.¹ In this immunosuppressed population, *Aspergillus* spp. – an opportunistic pathogen – can cause aggressive infections including sinusitis, tracheobronchitis, pneumonia, necrotizing cellulitis, brain abscess, or disseminated disease. In heart transplant (HT) recipients, *Aspergillus* spp. has been reported as the most common cause of invasive fungal infection and frequently causes pneumonia² with a high attributable mortality, ranging from 53% to 78%.³⁻⁵ Although invasive pulmonary aspergillosis (IPA) is a serious disease in this population, little is known about its natural history. The aim of this study was to further establish the characteristics of IPA infections and their outcomes in our center.

Methods

We conducted a retrospective chart review of patients who underwent heart transplantation at our center between

1998 and 2016 and who subsequently developed IPA. Cases were identified according to the clinical practice guidelines of the Infectious Diseases Society of America for IPA⁶ and the revised EORTC/MSG criteria for defining invasive fungal infection, including IPA.⁷ The diagnosis was considered definite when the patient had positive histology and culture of a sample obtained from the same site, or negative histology (or not performed) and positive culture results of a sample obtained by protocol-specified invasive techniques such as bronchoalveolar lavage (BAL). A galactomannan index of 1 or higher was regarded as positive and suggested a diagnosis of IPA.

Data collection included age, gender, primary cardiac diagnosis, date of transplantation, immunosuppressant regimen, cytomegalovirus (CMV) serological status, antifungal prophylaxis, known risk factors for IPA (including neutropenia), radiographic features, serum galactomannan level, bronchoscopy and microbiology data (Tables 1 and 2).

At our institution, by protocol all patients receive induction therapy with basiliximab and high doses of corticosteroids. Basiliximab is administered 4-6 hours after weaning from cardiopulmonary bypass. Initiation of calcineurin inhibitors is delayed until day 3 post-HT. Maintenance immunosuppressive therapy consists of corticosteroids, calcineurin inhibitors and cell cycle inhibitors. This immunosuppression regimen is based on the International Society of Heart and Lung Transplantation guidelines for the care of heart transplant recipients.⁸

Table 1 Demographic and clinical characteristics and laboratory features of the study population.

Case	Age, years	Gender	Indication	Days since transplantation	Prednisone dose	Immunosuppression	Leukocytes/neutrophils	Creatinine (mg/dl)
1	59	Male	Dilated cardiomyopathy	5	60	Cyclosporine + mycophenolate	9.5/-	1.6
2	70	Male	Dilated cardiomyopathy	12	50	Tacrolimus + mycophenolate	14.5/-	0.9
3	51	Male	Chagas cardiomyopathy	116	15	Tacrolimus + azathioprine	8.1/-	1.0
4	61	Male	Valvular cardiomyopathy	189	7.5	Tacrolimus + mycophenolate	2.9/1.2	1
5	71	Male	Ischemic cardiomyopathy	55	20	Tacrolimus + mycophenolate	12.2/10.8	1.6

In our HT protocol, all patients without risk factors for infection by filamentous fungi are prescribed fluconazole 100 mg/day during the first month, from day 1 post-transplant, while patients who are at risk for such infection (at least one of the following risk factors: administration of immunosuppression; acute renal failure requiring hemodialysis; colonization by filamentous fungi such as *Aspergillus*; retransplant or double transplant [heart and kidney or heart and liver]) receive antifungal prophylaxis with liposomal amphotericin B or micafungin.

In all patients under antifungal prophylaxis, fungal culture and staining with calcium fluoride from sputum or respiratory secretions, chest X-rays and serum galactomannan testing for *Aspergillus* are performed once a week while hospitalized. If the chest X-ray is doubtful, high-resolution chest computed tomography (CT) is performed.

Following hospital discharge, patients are followed at our center every month for the first six months after HT, every two months from the sixth to the twelfth month, and then every six months indefinitely. At each visit a comprehensive clinical assessment is performed including routine laboratory tests and a chest X-ray.

Results

Among 328 HTs performed between 1998 and 2016, we identified five cases of IPA. All cases were male, and mean age was 62 years (range 59-71 years). The most common indication for HT was non-ischemic dilated cardiomyopathy. Antifungal prophylaxis was started in all patients, but two patients did not complete the course since IPA was diagnosed in the first 30 days after transplantation. One patient required prophylaxis with micafungin due to acute renal failure.

The median time from transplantation to diagnosis was 55 days. Productive cough was reported as the main symptom in two patients, one patient presented atypical chest pain and the other two were asymptomatic. In one of the asymptomatic patients the diagnosis was suspected from abnormal findings (unilateral nodular opacities) on chest X-ray during a routine monthly follow-up visit. In all patients, the radiological assessment was based on chest X-ray and chest CT. The most commonly reported radiographic abnormality was multiple nodular opacities in both imaging techniques

(Figure 1). Halo sign was observed in one case (Figure 1B). Serum galactomannan level was abnormally high in three out of five patients. Bronchoscopy was performed in all patients and *A. fumigatus* was isolated on BAL culture in four cases. *Aspergillus* was demonstrated by polymerase chain reaction (PCR) in the patient in whom nodular lesions on the chest X-ray aroused suspicion of IPA.

Initial antifungal treatment included amphotericin in four patients, subsequently changed to voriconazole in three cases, and posaconazole in one patient, with total treatment lasting an average of 12 months. Two patients required the addition of caspofungin and one of anidulafungin as salvage therapy. Neutropenia was found in only one patient. Renal failure, defined as creatinine >1.5 mg/dl, was observed in two patients, and concurrent CMV infection in three patients. All patients were alive after a mean follow-up of 18 months.

Discussion

Since the introduction of HT as a therapeutic modality for end-stage heart failure in 1968, *Aspergillus* has been recognized as a major opportunistic pathogen with a high attributable mortality.⁵ Our series of five IPA cases shows unusually low mortality. There are several possible reasons for this. First, the number of reported cases is small; however, 100% survival appears optimistically high, and some fatality would be expected. Second, two patients were asymptomatic at the time of diagnosis, both with negative serum galactomannan, which indicates that treatment was initiated in good time. Also, four patients received combined treatment with two antifungals and only one patient was treated with just one drug.

The known risk factors for IPA in HT recipients include isolation of *A. fumigatus* in respiratory tract cultures prior to HT, reoperation, CMV disease, post-transplant hemodialysis, and cases of IPA in the institution in the two months before transplantation.⁷ In a study by Muñoz et al.,⁴ IPA-related mortality was 11/17 (65%), and total mortality was 17/27 (63%), but this cohort presented a high proportion of risk factors for IPA: hemodialysis in 19%, bacterial infection in 63%, and rejection episode in 44%. Also in this cohort, 82% of patients received either OKT3 or anti-thymocyte globulin as induction therapy. It is known that the stronger the

Table 2 Clinical course and treatment.

Case	Symptoms	Initial serum galactomannan level	Concurrent CMV infection	Confirmation test	Fungal prophylaxis	Chest X-ray	CT scan	Treatment	ISHLT rejection grade
1	Asymptomatic	0.13	Yes	BAL culture: <i>Aspergillus fumigatus</i>	Micafungin	None	Multiple micronodular opacities	Amphotericin B	1A
2	Productive cough	4.23	No	BAL culture: <i>A. fumigatus</i>	Fluconazole	Multiple nodular opacities	Multiple nodular opacities and a 45-mm mass with peripheral halo	Voriconazole + caspofungin	1A
3	Productive cough and fever	4.73	Yes	PCR (<i>A. fumigatus</i>)	Fluconazole	Multiple nodular opacities	Multiple nodular opacities (less than 10 mm)	Amphotericin + caspofungin	1B
4	Asymptomatic	0.91	No	BAL culture: <i>A. fumigatus</i>	Fluconazole	Unilateral nodular opacities	Multiple nodular opacities (less than 10 mm)	Voriconazole + anidulafungin	1A
5	Chest pain	5.0	Yes	BAL culture: <i>A. fumigatus</i>	Fluconazole	Unilateral nodular opacities	Ground-glass pattern	Amphotericin B	1A

BAL: bronchoalveolar lavage; CT: computed tomography; ISHLT: International Society of Heart and Lung Transplantation.; PCR: polymerase chain reaction.

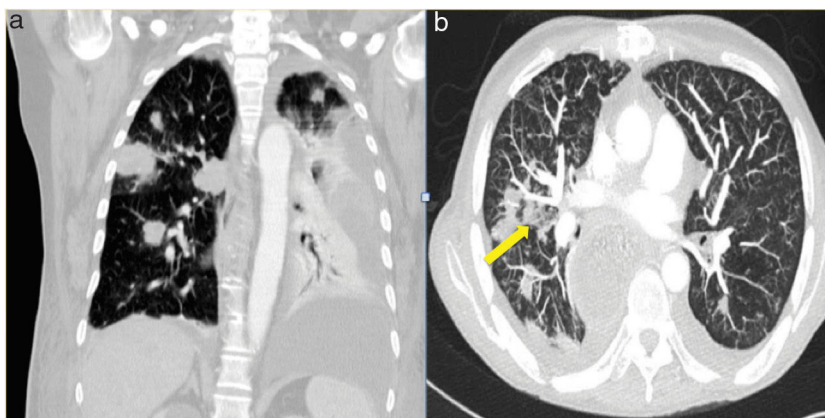


Figure 1 Chest computed tomography showing (A) multiple nodular opacities and (B) an incipient halo sign secondary to invasive pulmonary aspergillosis (yellow arrow).

immunosuppression, the higher the risk of infection. None of our patients needed hemodialysis, nor were there any rejection episodes requiring an increase in immunosuppression. Likewise, our patients received basiliximab instead of OKT3 or anti-thymocyte globulin. Basiliximab is associated with fewer infections overall than OKT3 or anti-thymocyte globulin in solid organ transplantation.⁹

Although this case series could have suffered from publication bias, we consider our results to be due to early diagnosis based on serum galactomannan level and prompt bronchoscopy followed by initiation of aggressive treatment, as well as the patients' clinical characteristics. Our findings can be summarized as improved outcomes resulting from early diagnosis, which has also been shown in patients with blood cancer and invasive fungal infections.

Finally, it appears that, as in many other fields of medicine, patients' prognosis is improving as we learn more about complications and as new diagnostic techniques lead to earlier initiation of modern therapeutic strategies. As Montoya et al.³ concluded, patients suffering IPA in recent years may have a better prognosis than those treated before. Have we reached the point when mortality from IPA is decreasing?

Conclusion

IPA is a potentially lethal complication after HT. Early diagnosis and prompt initiation of aggressive treatment are the cornerstone of better survival.

Conflicts of interest

The authors have no conflicts of interest to declare.

References

- O'Shea DT, Humar A. Life-threatening infection in transplant recipients. *Critical Care Clinics*. 2013;29:953–73.
- Denning DW. Invasive aspergillosis. *Clinical Infectious Diseases*. 1998;26:781–803.
- Flores-Umanzor E, Ivey-Miranda J, Pujol-Lopez M, Cepas-Guillen P, Fernandez-Valledor A, Caldentey G, et al. Invasive aspergillosis in the setting of cardiac transplantation. *Clinical infectious diseases: an official publication of the Infectious Diseases Society of America* 37 Suppl. 2003;3:S281–92.
- Muñoz P, Vena A, Ceron I, et al. Invasive pulmonary aspergillosis in heart transplant recipients: Two radiologic patterns with a different prognosis. *J Heart Lung Transplant*. 2014;33:1034–40.
- Gurwith MJ, Stinson EB, Remington JS. Aspergillus infection complicating cardiac transplantation. Report of five cases. *Arch Intern Med*. 1971;128:541–5.
- Walsh TJ, Anaissie EJ, Denning DW, et al. Treatment of aspergillosis: clinical practice guidelines of the Infectious Diseases Society of America. *Clin Infect Dis*. 2008;46:327–60.
- De Pauw B, Walsh TJ, Donnelly JP, et al. Revised definitions of invasive fungal disease from the European Organization for Research and Treatment of Cancer/Invasive Fungal Infections Cooperative Group and the National Institute of Allergy and Infectious Diseases Mycoses Study Group (EORTC/MSG) Consensus Group. *Clin Infect Dis*. 2008;46:1813–21.
- Costanzo MR, Dipchand A, Starling R, et al. The International Society of Heart and Lung Transplantation Guidelines for the care of heart transplant recipients. *J Heart Lung Transplant*. 2010;29:914–56.
- Koyawala N, Silber JH, Rosenbaum P, et al. Comparing outcomes between antibody induction therapies in kidney transplantation. *Journal of the American Society of Nephrology*, 28(7), 2188–2200. DOI: 10.1681/ASN.2016070768c Costanzo MR, et al. The International Society of Heart and Lung Transplantation Guidelines for the care of heart transplant recipients. *J Heart Lung Transplant* 2010;29:914–956.