

## IMAGE IN CARDIOLOGY

# Infant heart tumour

## Tumor cardíaco em lactente

Pedro Epifânio\*, Maria Emanuel Amaral, Natália Noronha, Andreia Francisco, Dina Rodrigues, António Pires, Eduardo Castela



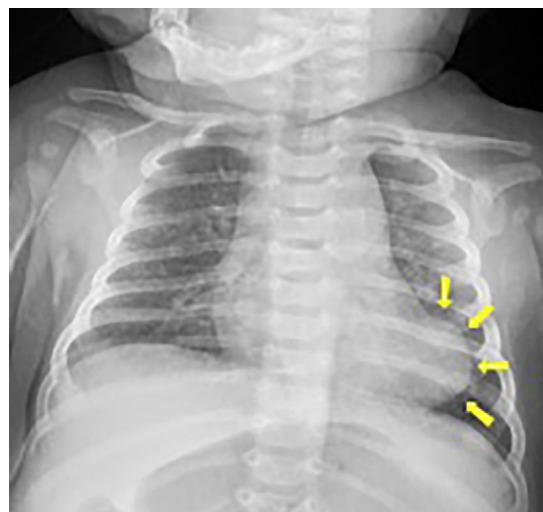
Hospital Pediátrico de Coimbra, Serviço de Cardiologia Pediátrica, Coimbra, Portugal

Received 31 October 2016; accepted 11 February 2017

We present the case of a two-month-old, previously healthy female infant seen in the emergency department with a lower respiratory tract infection. The chest X-ray showed bilateral interstitial peribronchial thickening and an abnormally shaped cardiac silhouette (Figure 1), for which she was referred for pediatric cardiology assessment.

The echocardiogram showed a 25×14 mm ovoid, heterogeneous echogenic intramyocardial mass localized to the apical LV lateral wall and also involving the base of the anterolateral papillary muscle. No extension of the mass was evident beyond the myocardium, and there was also no obstruction of the left ventricle inflow or outflow tract or mitral regurgitation (Figure 2). The electrocardiogram showed abnormal positive T wave in V1 and negative T waves in V2 to V6 and in leads I, II and aVL. No other abnormal findings were found.

In order to better characterize the mass, cardiac magnetic resonance imaging (CMRI) was performed (Figure 3) which confirmed the presence of an apical intramyocardial heterogeneous mass measuring 30×14 mm extending to the base of the anterolateral papillary muscle, with clear hypoperfusion on first-pass perfusion (FPP), surrounded by a rim of normally perfused myocardium, isointense on T1-weighted turbo spin-echo imaging (TSE) and slightly hyperintense on T2 TSE. Myocardial delayed enhancement



**Figure 1** Chest X-ray showing an abnormal left-sided cardiac silhouette.

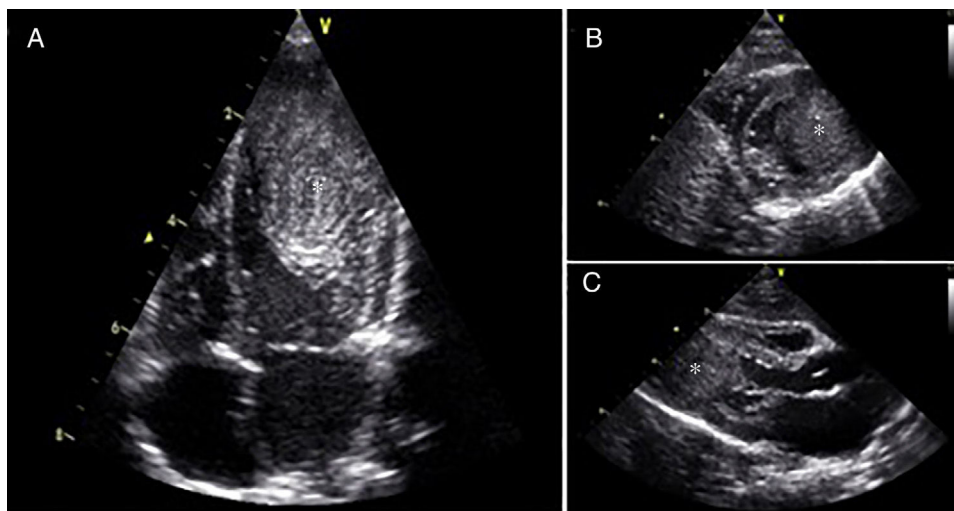
(MDE) showed very strong late gadolinium enhancement. The tissue characteristics were strongly suggestive of a cardiac fibroma.

Based on these findings and the fact that there were no clinical symptoms or signs of cardiac compromise we opted for a conservative approach.

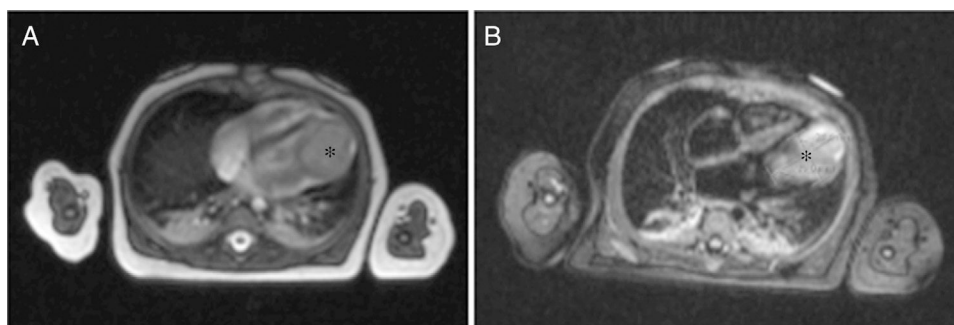
At the age of 9 months, follow-up echocardiogram showed that the mass measured 28×19 mm in diameter.

\* Corresponding author.

E-mail address: [p.pires.epifanio@gmail.com](mailto:p.pires.epifanio@gmail.com) (P. Epifânio).



**Figure 2** Transthoracic echocardiogram showing an intramyocardial left ventricle cardiac mass (\*) involving the base of the anterolateral papillary muscle. A – apical 4-chamber view; B – parasternal short axis view; C – parasternal long axis view.



**Figure 3** Cardiac magnetic resonance imaging in 4-chamber view showing an apical intramyocardial heterogeneous mass (\*). A – First-pass perfusion; B – Myocardial delayed enhancement.

The infant remains asymptomatic with normal left ventricle function, no outflow tract obstruction and no mitral valve regurgitation.

### Conflicts of interest

The authors have no conflicts of interest to declare.