



ORIGINAL ARTICLE

Combined MitraClip implantation and left atrial appendage occlusion using the Watchman device: A case series from a referral center



Ana Rita G. Francisco^{a,*}, Eduardo Infante de Oliveira^a, Miguel Nobre Menezes^a, Pedro Carrilho Ferreira^a, Pedro Canas da Silva^a, Ângelo Nobre^b, Fausto J. Pinto^a

^a Cardiology Department, Santa Maria University Hospital, CHLN, CAML, CCUL, Faculty of Medicine, University of Lisbon, Lisbon, Portugal

^b Cardiothoracic Surgery Department, Santa Maria University Hospital, CHLN, CAML, CCUL, Faculty of Medicine, University of Lisbon, Portugal

Received 2 August 2016; accepted 11 November 2016

Available online 30 June 2017

KEYWORDS

Mitral regurgitation;
MitraClip;
Left atrial appendage
occlusion;
Watchman

Abstract

Introduction: Patients referred for percutaneous transcatheter mitral valve repair using the MitraClip[®] system frequently have atrial fibrillation, which imposes additional challenges due to the need for oral anticoagulation. Left atrial appendage occlusion is currently regarded as a non-inferior alternative to anticoagulation in patients with non-valvular atrial fibrillation and both high thromboembolic and bleeding risk. Considering that both MitraClip implantation and left atrial appendage occlusion are percutaneous techniques that require transseptal puncture, it is technically attractive to consider their concomitant use.

Objectives: We aim to evaluate the feasibility of a combined approach with MitraClip implantation and left atrial appendage occlusion in a single procedure.

Methods: We report the first case series regarding this issue, discussing the specific advantages, pitfalls and technical aspects of combining these two procedures.

Results: Five patients underwent left atrial appendage occlusion with the Watchman[®] device followed by MitraClip implantation in the same procedure. All patients experienced significant reduction in mitral valve regurgitation of at least two grades, optimal occluder position, no associated complications and significant clinical improvement assessed by NYHA functional class (reduction of at least one functional class, with four patients in class I at one-month follow-up).

* Corresponding author.

E-mail address: ana.r.francisco@gmail.com (A.R.G. Francisco).

PALAVRAS-CHAVE

Regurgitação mitral;
MitraClip;
 Encerramento do
 apêndice auricular
 esquerdo;
Watchman

Conclusion: In selected patients rejected for surgical mitral valve repair, with atrial fibrillation and increased risk of bleeding and embolic events, a combined approach with *MitraClip* implantation and left atrial appendage occlusion in a single procedure is feasible, safe and effective.

© 2017 Sociedade Portuguesa de Cardiologia. Published by Elsevier España, S.L.U. All rights reserved.

Implantação simultânea de *MitraClip* e encerramento do apêndice auricular esquerdo com *Watchman*: a experiência de um centro de referência

Resumo

Introdução: Os doentes referenciados para reparação mitral percutânea, usando o sistema *MitraClip*, têm frequentemente fibrilhação auricular, com desafios adicionais devido à necessidade de anticoagulação. O encerramento percutâneo do apêndice auricular esquerdo é, atualmente, uma alternativa não inferior à anticoagulação em doentes com fibrilhação auricular não valvular, com elevado risco quer tromboembólico quer hemorrágico. Considerando que estas duas técnicas (*MitraClip* e encerramento percutâneo do apêndice auricular esquerdo) requerem punção transeptal, é tecnicamente atrativo considerar o seu uso concomitante.

Objectivos: Avaliar a exequibilidade de efectuar no mesmo procedimento implantação de *MitraClip* e encerramento percutâneo do apêndice auricular esquerdo.

Métodos: Descrição da primeira série de casos sobre a aplicação destas duas técnicas num só procedimento, com análise das vantagens, dificuldades e aspetos técnicos.

Resultados: Cinco doentes foram submetidos a encerramento percutâneo do apêndice auricular esquerdo com dispositivo *Watchman*, seguido de implantação de *MitraClip* no mesmo procedimento. Em todos os doentes verificou-se redução significativa do grau da regurgitação mitral em pelo menos dois graus, posição ótima do sistema de oclusão do apêndice, sem complicações associadas e com melhoria clínica significativa avaliada pela classe funcional de NYHA (redução de pelo menos uma classe funcional, com quatro doentes em classe funcional I no final do primeiro mês de seguimento).

Conclusão: Em doentes selecionados, recusados para reparação cirúrgica da valvular mitral, com fibrilhação auricular e risco elevado de eventos hemorrágicos e embólicos, uma abordagem combinada com implantação de *MitraClip* e encerramento percutâneo do apêndice auricular esquerdo num só procedimento é viável, segura e eficaz.

© 2017 Sociedade Portuguesa de Cardiologia. Publicado por Elsevier España, S.L.U. Todos os direitos reservados.

ACC	American College of Cardiology
AF	atrial fibrillation
AHA	American Heart Association
ESC	European Society of Cardiology
KDOQI	Kidney Disease Outcomes Quality Initiative
LAA	left atrial appendage
LSPV	left superior pulmonary vein
LVEF	left ventricular ejection fraction
MR	mitral regurgitation
MVR	mitral valve repair
NYHA	New York Heart Association
OAC	oral anticoagulation
TEE	transesophageal echocardiography

Introduction

Percutaneous transcatheter mitral valve repair (MVR) using the *MitraClip*[®] system is an emerging approach to treat selected cases of degenerative and functional mitral regurgitation (MR). Its safety and efficacy in high risk-patients has been consistently demonstrated, both in clinical trials and in real-world settings.¹⁻³ The procedure has been recommended by the European Society of Cardiology (ESC) and the European Association for Cardio-Thoracic Surgery (EACTS) since 2012 for patients with both primary and secondary severe MR at high surgical risk (class IIb, level of evidence C).⁴ Following approval by the US Food and Drug Administration (FDA) in 2013, the *MitraClip* was also recommended in the 2014 American College of Cardiology (ACC)/American Heart Association (AHA) guidelines for degenerative MR (class IIb, level of evidence B).⁵

Patients referred for MitraClip implantation frequently have concomitant atrial fibrillation (AF). These patients present high surgical risk due to the association of various comorbidities, as well as a frailty profile that represents increased risk of thromboembolic and bleeding events. These characteristics pose additional challenges due to the need for chronic oral anticoagulation (OAC).

Left atrial appendage (LAA) occlusion, either percutaneously or surgically, is currently regarded as an alternative to OAC in patients with non-valvular AF.⁶ Similarly to the MitraClip, this was as a result of two trials^{7,8} and several registries.⁹⁻¹² The ESC guidelines issued a class IIb recommendation regarding this procedure,¹³ and it obtained FDA approval in 2015.

The frequent association of MR and AF has often led surgeons to excise the LAA during heart surgery.¹⁴ Considering that both MitraClip implantation and LAA occlusion are percutaneous techniques that require transseptal puncture and access to the left atrium, it is technically attractive to consider emulating the surgical approach percutaneously. With the exception of two single case reports, there are no other published data regarding the feasibility, safety and efficacy of a combined procedure.^{15,16} In this article, we report the first case series regarding this issue, discussing the specific advantages, pitfalls and technical aspects of combining these two procedures.

Methods

We performed a retrospective single-center study of consecutive patients with severe MR and AF undergoing MitraClip device implantation plus LAA occlusion with the Watchman[®] device. Baseline clinical, echocardiographic, hemodynamic and procedural data were recorded retrospectively through reviews of hospital records. Echocardiographic assessment was repeated after the procedure, on the same day and at one-month follow-up. Acute and one-month results were analyzed.

Results

Five patients with severe MR and AF rejected for surgical MVR were referred for percutaneous MVR. After assessment by the interventional cardiology team, they were also selected for LAA occlusion on the basis of high thromboembolic risk combined with high bleeding risk. [Table 1](#) shows the baseline patient characteristics.

Patient 1 was a 57-year-old man with alcoholic dilated cardiomyopathy, severely compromised left ventricular ejection fraction (LVEF) and severe functional MR. Cardiac resynchronization therapy and atrioventricular node ablation had already been performed. Concomitantly he had permanent AF, liver cirrhosis (Child-Pugh class B) without esophageal varices (with continued alcohol abuse), previous ischemic stroke under OAC, chronic renal disease (Kidney Disease Outcomes Quality Initiative [KDOQI] stage 3b), pulmonary and systemic hypertension, dyslipidemia and previous resection of colon cancer.

Patient 2 was a 72-year-old man with ischemic dilated cardiomyopathy and moderately depressed LVEF, with a cardiac defibrillator system implanted for primary prevention

and severe functional MR with episodes of flash edema. He had previously undergone triple coronary artery bypass graft surgery. Other comorbidities were permanent AF, pulmonary and systemic hypertension, dyslipidemia, chronic kidney disease (KDOQI stage 3a), chronic iron deficiency anemia with intestinal angiodysplasia and previous smoking.

Patient 3 was a 76-year-old woman with non-ischemic dilated cardiomyopathy, severely depressed LVEF and severe functional MR, who had already undergone cardiac resynchronization therapy. She also had permanent AF with labile INR under warfarin (TTR <60%), pulmonary and systemic hypertension, dyslipidemia and chronic kidney dysfunction (KDOQI stage 3a), and chronic use of non-steroidal anti-inflammatory drugs due to osteoarthicular disease.

Patient 4 was a 78-year-old man with non-ischemic dilated cardiomyopathy, severely depressed LVEF and severe functional MR. Concomitant comorbidities were permanent AF with labile INR under warfarin (TTR <60%), pulmonary and systemic hypertension, chronic kidney dysfunction (KDOQI stage 3b) and dyslipidemia.

Patient 5 was a 71-year-old man with ischemic dilated cardiomyopathy, severely depressed LVEF and severe functional MR. Concomitant comorbidities were previous ischemic stroke, permanent AF, systemic hypertension, chronic kidney dysfunction (KDOQI stage 3a) and dyslipidemia.

Overall, the patients had significant comorbidities, LVEF <35% and severe functional MR, and were severely symptomatic (NYHA class III or IV). They had a high risk of both thromboembolic and bleeding events, with mean CHA₂DS₂-VASc score of 4.5±0.6 and mean HAS-BLED score of 3.5±0.6. The mean annual stroke risk predicted by CHA₂DS₂-VASc was 6.0±1.4%, with a higher annual risk of major bleeding events predicted by HAS-BLED (6.2±2.9%).

Procedural details

The procedure was performed under general anesthesia in the cardiac catheterization laboratory, with three-dimensional transesophageal echocardiography (TEE) guidance for MitraClip deployment and fluoroscopic guidance. In all cases LAA occlusion was performed first. Procedural details are displayed in [Table 2](#).

Vascular access

By protocol, right radial arterial access (4F sheath) was established for invasive blood pressure monitoring, except for one case in which access was via the right femoral artery (4F sheath) due to inability to obtain radial access. Venous access was via the right femoral vein (6F sheath) in all cases. After establishment of arterial and venous access, an intravenous unfractionated heparin bolus was administered (50% of the total recommended dose – 100 U/kg).

Transseptal puncture

Transseptal puncture, guided by TEE, was performed through an 8F SL1 sheath (St. Jude Medical) with a BRK transseptal needle (St. Jude Medical). The puncture was

Table 1 Baseline patient characteristics.

	Patient 1	Patient 2	Patient 3	Patient 4	Patient 5
<i>Age, years</i>	57	72	76	78	71
<i>Gender</i>	Male	Male	Female	Female	Male
<i>AF classification</i>	Permanent	Permanent	Permanent	Permanent	Permanent
<i>LVEF, %</i>	24	35	20	30	23
<i>NYHA class</i>	III/IV	III/IV	III/IV	II/IV	III/IV
<i>Cardiomyopathy etiology</i>	Alcoholic dilated	Ischemic dilated	Non-ischemic dilated	Non-ischemic dilated	Ischemic dilated
Comorbidities					
Hypertension	Yes	Yes	Yes	Yes	Yes
Pulmonary hypertension	Yes	Yes	Yes	Yes	Yes
Diabetes	No	Yes	No	No	No
Previous stroke	Yes	No	No	No	Yes
Renal disease, KDOQI stage	3b	3a	3a	3b	3a
Previous open heart surgery	No	Yes	No	No	Yes
Chronic liver disease	Yes	No	No	No	No
Chronic anemia	No	Yes	No	No	No
Malignancy	Yes	No	No	No	No
<i>CHADS₂ score</i>	4	3	3	3	4
<i>Annual stroke risk, %¹⁵</i>	8.5	5.9	5.9	5.9	8.5
<i>CHA₂DS₂-VASC score</i>	4	5	5	4	6
<i>Annual stroke risk, %¹⁷</i>	4	6.7	6.7	4	9.7
<i>Previous embolic event under OAC</i>	Yes	No	No	No	Yes
<i>HAS-BLED score</i>	4	3	3	3	3
<i>Annual bleeding risk, %¹⁸</i>	8.9	5.8	5.8	5.8	5.8
Age >65 years	No	Yes	Yes	Yes	Yes
Previous stroke	Yes	No	No	No	Yes
Prior bleeding or predisposition	No	Yes	No	No	No
Renal dysfunction (Cr >2.36 mg/dl)	Yes	No	No	Yes	No
Liver dysfunction (cirrhosis)	Yes	No	No	No	No
Labile INR (TTR <60%)	No	No	Yes	Yes	No
Drugs predisposing to bleeding	Yes	No	No	No	Yes
Alcohol abuse	Yes	No	No	No	No
<i>Previous bleeding event under OAC</i>	No	No	No	No	No

AF: atrial fibrillation; Cr: serum creatinine; INR: international normalized ratio; KDOQI: Kidney Disease Outcomes Quality Initiative; LVEF: left ventricular ejection fraction; NYHA: New York Heart Association; OAC: oral anticoagulation; TTR: time in therapeutic range.

performed aiming for the optimal position for MitraClip implantation.

The remaining dose of intravenous unfractionated heparin was then administered and an activated clotting time of 250-300 s was maintained throughout the procedure.

Once access to the left atrium was achieved, an Amplatzer stiff wire was advanced into the left superior pulmonary vein (LSPV).

Left atrial appendage occlusion

For LAA occlusion, a Watchman 14F double curve access sheath was used followed by angiography of the LAA with a pigtail catheter. The LAA closure device size was selected after assessing the following LAA features by TEE: ostium size and shape, and number of lobes and length in at least four TEE views (0°, 45°, 90° and 135°). These measurements were complemented by angiography of the LAA. The device

was implanted under angiographic and echocardiographic (TEE) guidance using the standard technique. Criteria of success were achieved in all five patients. Only one device per patient was used, with appropriate stability, compression and sealing. No residual leaks or immediate complications were noted.

MitraClip procedure

The Watchman 14F double curve sheath was exchanged for a 24F MitraClip Guide Catheter, over an Amplatzer support wire positioned in the LSPV. A standard technique was used, under angiographic and TEE guidance.

The procedure steps are summarized in [Figure 1](#).

Three patients received only one clip, while the other two required two and three clips, respectively. All patients showed significant improvement in MR, three of them with residual grade I/IV regurgitation and the other two with

Table 2 Procedural details.

	Patient 1	Patient 2	Patient 3	Patient 4	Patient 5
Procedure time, min	194	67	76	75	81
Fluoroscopy time, min	21.7	20.4	15.9	27.7	16.4
Radiation dose, $\mu\text{Gy}/\text{cm}^2$	18.8	14.3	5.9	14.6	10.2
Arterial access	Right femoral, 4F	Right radial, 4F	Right radial, 4F	Right radial, 4F	Right radial, 4F
Venous access	Right femoral	Right femoral	Right femoral	Right femoral	Right femoral
MitraClip implantation					
<i>Number of devices</i>	3	1	2	1	1
MR					
Etiology	Functional	Functional	Functional	Functional	Functional
Pre-procedure grade	III/IV	IV/IV	IV/IV	III/IV	III/IV
Post-procedure grade	I-II/IV	II/IV	I/IV	I/IV	I/IV
Mean post-procedure gradient, mmHg	2.0	3.8	2.8	2.0	2.2
LAA occlusion (Watchman device)					
<i>Size of implanted device (mm)</i>	27	27	30	27	27
<i>Number of devices</i>	1	1	1	1	1
<i>Compression rate, %</i>	15	11	26	13	18
<i>Residual leak</i>	No	No	No	No	No
<i>Success</i>	Yes	Yes	Yes	Yes	Yes
Antithrombotic therapy	Warfarin	Dabigatran	Warfarin	Warfarin	Dabigatran
Complications	No	No	No	No	No

LAA: left atrial appendage; MR: mitral regurgitation.

grade II/IV. This goal was achieved without significant stenosis, mean final transvalvular gradient being 2.7 ± 0.9 mmHg. No complications occurred. Of note, there was no interference of the MitraClip delivery system with the implanted Watchman device.

Hemostasis

In all patients, the Perclose Proglide suture-mediated closure system (Abbott Vascular) was used for hemostasis of the femoral vein access site (two systems were pre-deployed, before insertion of the transseptal puncture sheath). Hemostasis of the arterial access site was performed by manual compression.

Follow-up

All patients were discharged 24-36 hours after the procedure. They started anticoagulation with warfarin or

non-vitamin K antagonist oral anticoagulants, according to the choice of the attending cardiologist, with later transition to antiplatelet therapy after TEE follow-up (PROTECT AF strategy).¹⁰

Patients underwent clinical and echocardiographic (TEE) follow-up one month after the procedure. Results were excellent in all patients, with clinical symptomatic improvement (NYHA class I-II/IV), significant MR reduction (without significant stenosis), optimal occluder position, no thrombus and no clinical events. The interatrial septum showed a small, not hemodynamically relevant, left-to-right shunt. Details are shown in Table 3. In a mean clinical follow-up of 243 ± 70.7 days, the symptomatic improvement was maintained, without adverse events.

Discussion and limitations

In this case series, we demonstrate the safety and effectiveness of combining percutaneous MVR using the MitraClip

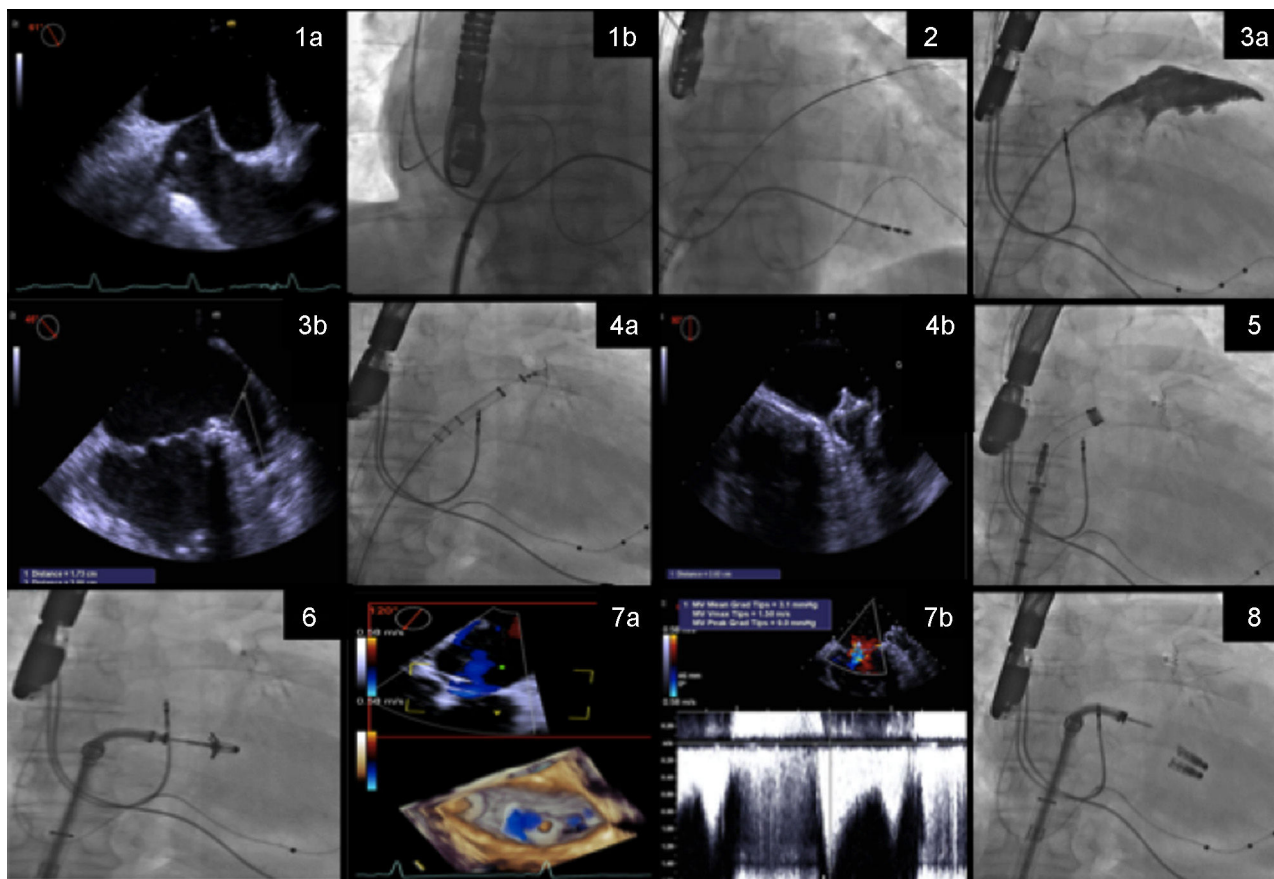


Figure 1 Procedure steps: (1) transseptal puncture guided by transesophageal echocardiography (TEE) (1a) and fluoroscopy (1b); (2) the Watchman 14F double curve sheath is advanced over an Amplatzer stiff wire positioned in the left superior pulmonary vein; (3) the left atrial appendage is measured by angiography (3a) and TEE (3b); (4) the Watchman is implanted guided by fluoroscopy (4a) and good apposition and absence of leaks and complications are confirmed by TEE (4b); (5) the Watchman 14F double curve sheath is exchanged for a 24F MitraClip guide catheter, over an Amplatzer support wire; (6) the clip delivery system is directed to the mid scallops of the anterior and posterior mitral valve leaflets, and guided by three-dimensional TEE, the clip is positioned above the origin of the mitral regurgitation (MR) jet; (7) leaflet insertion, MR reduction, and absence of significant mitral valve stenosis are confirmed by TEE (7a and 7b); (8) additional clips are deployed if necessary.

Table 3 Results at one-month follow-up.

	Patient 1	Patient 2	Patient 3	Patient 4	Patient 5
<i>NYHA class</i>	I/IV	II/IV	I/IV	I/IV	I/IV
<i>Embolic events</i>	No	No	No	No	No
<i>Bleeding events</i>	No	No	No	No	No
<i>Mitral valve</i>					
MR grade	I/IV	II/IV	I/IV	I/IV	II/IV
Mean gradient, mmHg	1.0	4.6	1.7	1.6	2.1
<i>LAA occlusion – Watchman device</i>					
Leaks	No	No	No	No	No
Thrombus	No	No	No	No	No

LAA: left atrial appendage; MR: mitral regurgitation; NYHA: New York Heart Association.

device and LAA occlusion with the Watchman device. It is should be noted that this approach produced excellent immediate and short-term results despite the severe cardiac and non-cardiac comorbidities of this cohort. These

results are in agreement with the few published single case reports.^{15,16}

Surgeons have long performed the combination of MVR, maze operation and LAA exclusion in patients with MR and

AF, and LAA occlusion is recommended in patients with AF who undergo heart surgery.¹³ The LAA is easily accessible to the surgeon, the occlusion procedure is reasonably safe and it is believed to decrease embolic risk even in the presence of valvular AF. However, variability in surgical approaches means that remnants of the LAA are often left behind, which might explain the poor long-term results of this approach.¹⁴ During MitraClip implantation, the LAA is also easily accessible to the interventional cardiologist and the etiology of AF is non-rheumatic. In summary, the patient is anesthetized, the transseptal puncture has been performed and the LAA is easily accessible to catheter treatment. Percutaneous LAA occlusion has a solid scientific basis and good long-term results regarding both safety and efficacy. Therefore, combining MitraClip implantation and percutaneous LAA occlusion seems at least as appealing as combining surgical MVR and LAA excision.

From a clinical standpoint, patients referred for MitraClip implantation frequently present a profile suitable for LAA occlusion (AF with high thromboembolic and bleeding risk due to the comorbidities that excluded them from surgical MVR). Exposing these patients to two separate procedures would present several disadvantages. It is well recognized that transseptal puncture carries a small but important risk of significant complications.¹⁹ Furthermore, the use of large sheaths in two different locations may increase the risk of significant residual septal shunting. A single procedure involves a single transseptal puncture, thereby minimizing both risks. Also, both procedures require large sheaths placed in femoral veins. Combining the two procedures streamlines vascular access and reduces the risk of complications. Finally, overall fluoroscopy time may be reduced compared to two individual procedures, due to the common initial pathway of both techniques.

Our results seem to confirm these advantages, as there were no complications regarding any of the above-mentioned issues and total fluoroscopy time and radiation dosages were acceptable.

On the other hand, theoretically there are potential disadvantages. First, the high transseptal puncture for the MitraClip is less well suited for LAA occlusion. Second, overall procedure time may be prolonged, with an added risk of volume overload or hemodynamic instability, especially considering the severely depressed systolic function of many of these patients. We experienced no difficulties with either issue, and overall procedure time was acceptable (103.0 ± 60.8 min). Nonetheless, acknowledging these pitfalls is essential for avoiding complications.

Another aspect of the technique that is the subject of debate is the appropriate sequence of procedures in this combined approach. Our team decided to perform LAA occlusion before MitraClip implantation based on the rationale of using sheaths with sequentially increasing diameters. We considered that this strategy would reduce the risk of bleeding at the access site and would impose less trauma on the atrial septum. Reversing the order of the procedures may have the advantage of eliminating the risk of interference of the MitraClip delivery system with the implanted Watchman device. However, we found that the presence of the Watchman device served as a useful anatomical reference during manipulation of the MitraClip delivery system. Performing the MitraClip implantation first would require an exchange

for a shorter sheath compatible with the 14F Watchman delivery sheath, to avoid massive bleeding at the access site. Alternatively, the 24F could be exchanged directly for the 14F using the pre-deployed Perclose Proglide systems to close the orifice around the sheath. This approach may compromise final access occlusion success.

Conclusion

In selected patients at high risk for MR surgery who concomitantly present AF and an increased risk of both bleeding and embolic events, a combined approach with MitraClip and Watchman Occluder implantation in a single procedure is feasible, safe and effective, in both immediate and short-term follow-up, when undertaken by an experienced team.

Ethical disclosures

Protection of human and animal subjects. The authors declare that no experiments were performed on humans or animals for this study.

Confidentiality of data. The authors declare that they have followed the protocols of their work center on the publication of patient data.

Right to privacy and informed consent. The authors have obtained the written informed consent of the patients or subjects mentioned in the article. The corresponding author is in possession of this document.

Funding

No specific funding grants were used regarding this study.

Conflicts of interest

Ana Rita G. Francisco has no conflicts of interest to declare; Eduardo Infante de Oliveira has received speaker/proctor honoraria and research grants from Boston Scientific and speaker honoraria from Abbott Vascular; Miguel Nobre Menezes has no conflicts of interest to declare; Pedro Carrilho Ferreira has received speaker honoraria and research grants from Boston Scientific; Pedro Canas da Silva has received speaker honoraria and research grants from Boston Scientific and Abbott Vascular.

References

1. Mauri L, Garg P, Massaro JM, et al. The EVEREST II trial: design and rationale for a randomized study of the E-Valve MitraClip system compared with mitral valve surgery for mitral regurgitation. *Am Heart J.* 2010;160:23–9.
2. Mauri L, Foster E, Glower DD, et al. 4-Year results of a randomized controlled trial of percutaneous repair versus surgery for mitral regurgitation compared with mitral valve surgery for mitral regurgitation. *J Am Coll Cardiol.* 2013;62:317–28.
3. Maisano F, Franzen O, Baldus S, et al. Percutaneous mitral valve interventions in the real world: early and 1-year results from the ACCESS-EU, a prospective, multicenter, nonrandomized

- post-approval study of the MitraClip therapy in Europe. *J Am Coll Cardiol*. 2013;62:1052–61.
4. Vahanian A, Alfieri O, Andreotti F, et al. Guidelines on the management of valvular heart disease (version 2012). Joint Task Force on the Management of Valvular Heart Disease of the European Society of Cardiology (ESC); European Association for Cardio-Thoracic Surgery (EACTS). *Eur Heart J*. 2012;33:2451–96.
 5. Nishimura RA, Otto CM, Bonow RO, et al. 2014 AHA/ACC Guideline for the Management of Patients With Valvular Heart Disease: Executive Summary: a report of the American College of Cardiology/American Heart Association Task Force on Practice Guidelines. *Circulation*. 2014;129:2440–92.
 6. Tzikas A, Sievert H, Holmes DR Jr. Percutaneous left atrial appendage occlusion in 2016. *EuroIntervention*. 2016;11:e1576–8.
 7. Holmes DR, Reddy VY, Turi ZG, et al., PROTECT AF Investigators. Percutaneous closure of the left atrial appendage versus warfarin therapy for prevention of stroke in patients with atrial fibrillation: a randomised non-inferiority trial. *Lancet*. 2009;374:534–42.
 8. Holmes DR Jr, Kar S, Price MJ, et al. Prospective randomized evaluation of the Watchman Left Atrial Appendage Closure device in patients with atrial fibrillation versus long-term warfarin therapy: the PREVAIL trial. *J Am Coll Cardiol*. 2014;64:1–12.
 9. Boersma LV, Schmidt B, Betts TR, et al. Implant success and safety of left atrial appendage closure with the WATCHMAN device: peri-procedural outcomes from the EWOLUTION registry. *Eur Heart J*. 2016;ehv730.
 10. Reddy VY, Holmes D, Doshi SK, et al. Safety of percutaneous left atrial appendage closure: results from the Watchman Left Atrial Appendage System for Embolic Protection in Patients with AF (PROTECT AF) clinical trial and the Continued Access Registry. *Circulation*. 2011;123:417–24.
 11. Urena M, Rodés-Cabau J, Freixa X, et al. Percutaneous left atrial appendage closure with the AMPLATZER cardiac plug device in patients with nonvalvular atrial fibrillation and contraindications to anticoagulation therapy. *J Am Coll Cardiol*. 2013;62:96–102.
 12. Tzikas A, Shakir S, Gafoor S, et al. Left atrial appendage occlusion for stroke prevention in atrial fibrillation: multicentre experience with the AMPLATZER Cardiac Plug. *EuroIntervention*. 2015;10.
 13. Kirchhof P, Benussi S, Kotecha D, et al. 2016 ESC Guidelines for the management of atrial fibrillation developed in collaboration with EACTS. *Eur J Cardiothorac Surg*. 2016;50:e1–88.
 14. Cullen MW, Stulak JM, Li Z, et al. Left atrial appendage patency at cardioversion after surgical left atrial appendage intervention. *Ann Thorac Surg*. 2016;101:675–81.
 15. Schade A, Kerber S, Hamm K. Two in a single procedure: combined approach for MitraClip implantation and left atrial appendage occlusion using the Watchman device. *J Invasive Cardiol*. 2014;26:E32–4.
 16. Puls M, Seipelt R, Schillinger W. Complete interventional heart repair of multiple concomitant cardiac pathologies in a staged approach. *Catheter Cardiovasc Interv*. 2013;81:896–900.
 17. Lip GY, Nieuwlaat R, Pisters R, et al. Refining clinical risk stratification for predicting stroke and thromboembolism in atrial fibrillation using a novel risk factor-based approach: the euro heart survey on atrial fibrillation. *Chest*. 2010;137:263–72.
 18. Lip GY, Frison L, Halperin JL, et al. Comparative validation of a novel risk score for predicting bleeding risk in anticoagulated patients with atrial fibrillation: the HAS-BLED (Hypertension, Abnormal Renal/Liver Function, Stroke, Bleeding History or Predisposition, Labile INR, Elderly, Drug/Alcohol Concomitantly) score. *J Am Coll Cardiol*. 2011;57:173–80.
 19. Katritsis GD, Siontis GC, Giazitzoglou E, et al. Complications of transseptal catheterization for different cardiac procedures. *Int J Cardiol*. 2013;168:5352–4.