

IMAGE IN CARDIOLOGY

Active fixation coronary sinus lead extraction – A safe procedure



Extração de eletrocater com sistema de fixação ativa do seio coronário – um procedimento seguro

Tatiana Guimarães*, Gustavo Lima da Silva, Ana Bernardes, João de Sousa, Pedro Marques

Serviço de Cardiologia, Hospital de Santa Maria, Centro Académico Médico de Lisboa, CCUL, Lisboa, Portugal

Received 12 October 2015; accepted 20 December 2015
Available online 4 August 2016

The first active fixation coronary sinus lead was introduced in 2008 (Medtronic Inc., Attain StarFix 4195). Initial enthusiasm for this method of avoiding lead dislodgement was soon replaced by concerns about safety in the event of need for extraction.

The StarFix is a 5F unipolar lead, with a distal active fixation mechanism consisting of deployable lobes that expand to 24F. Deployment is achieved by advancing the outer tubing of the lead. Pulling the lead and advancing the tubing achieves acute repositioning. This mechanism for retraction of the lobes cannot be used in chronically implanted leads due not only to fibrosis involving the lobes but also to the low tension applied on them by the lead being completely inserted in the outer tubing. In our experience we have successfully extracted two of these leads (due to system infection), both implanted for more than 24 months. Extraction was performed in both cases by retracting the fixation lobes. This was achieved by progressively cutting the outer tubing and pressuring the lead with a stylet. After complete retraction of the lobes the lead was pulled out by smooth traction using a lead locking device (LLD®, Spectranetics) (Figures 1–4).

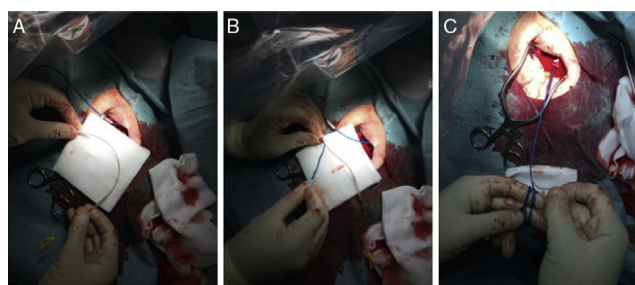


Figure 1 (A–C) Cutting the outer tubing and pressuring the lead with a stylet.

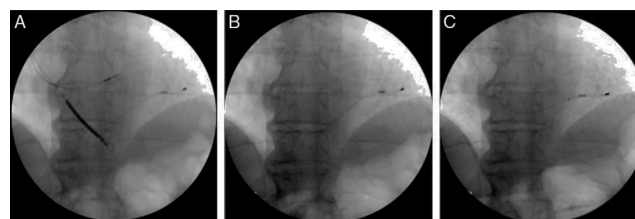


Figure 2 Fluoroscopic imaging: (A) complete triple-site cardiac resynchronization therapy defibrillator system; (B) active fixation coronary sinus lead, after extraction of both right ventricular leads; (C) initial retraction of the active fixation lead lobes.

* Corresponding author.
E-mail address: tatiana.oliveira.guimaraes@gmail.com
(T. Guimarães).

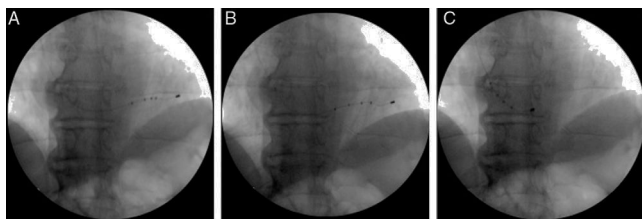


Figure 3 Fluoroscopic imaging: (A and B) sequential retraction of the active fixation lead lobes; (C) complete retraction of the lobes and pulling of the lead into the right atrium.

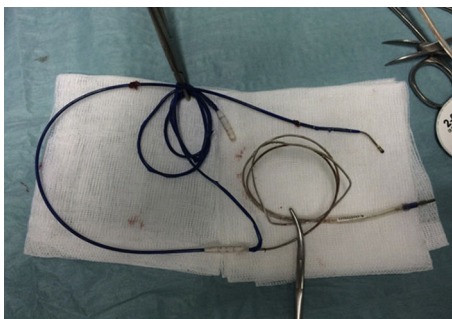


Figure 4 Active fixation coronary sinus lead after extraction.

Ethical disclosures

Protection of human and animal subjects. The authors declare that no experiments were performed on humans or animals for this study.

Confidentiality of data. The authors declare that no patient data appear in this article.

Right to privacy and informed consent. The authors declare that no patient data appear in this article.

Conflicts of interest

The authors have no conflicts of interest to declare.