



IMAGE IN CARDIOLOGY

Bilateral aneurysmatic coronary artery-pulmonary artery trunk fistulae



Fístulas aneurismáticas bilaterais entre as artérias coronárias e tronco da artéria pulmonar

Milan Satendra^{a,*}, Catarina Sousa^a, Ana G. Almeida^a, Paula Campos^b,
Luís Parente Martins^a, Roberto Palma Reis^a

^a Serviço de Cardiologia, Centro Hospitalar Lisboa Norte, Lisboa, Portugal

^b Serviço de Radiologia, Centro Hospitalar Lisboa Norte, Lisboa, Portugal

Received 1 December 2014; accepted 2 January 2015

Available online 6 July 2015

A 54-year-old asymptomatic woman presented to our echocardiography department for assessment of a continuous heart murmur. The transthoracic echocardiogram in parasternal short-axis view (Figure 1A) revealed a tunnel-like communication between the pulmonary artery trunk and the pericardial space (maximum width 8 mm). Color Doppler showed turbulent flow and pulsed wave Doppler showed typical continuous flow (Figure 1B). No valvular abnormalities were noted. There was a normal balance between the right and left ventricle, with preserved global systolic function. The estimated shunt by Qp/Qs was 1.3:1.0. The cardiac computed tomography scan revealed a large coronary artery fistula (CAF) between the left descending coronary artery and pulmonary artery trunk and also an aneurysmatic, tortuous CAF between the right coronary artery and pulmonary artery trunk (Figure 1C–F). A maximal exercise test was performed that excluded myocardial ischemia. She is currently asymptomatic and no cardiac events were noted in two-year follow-up.

We present this case because bilateral coronary to pulmonary artery fistulae are a very rare entity. CAFs found

to originate from both coronary arteries are rare and the pulmonary vasculature is the most uncommon site of termination.

Ethical disclosures

Protection of human and animal subjects. The authors declare that the procedures followed were in accordance with the regulations of the relevant clinical research ethics committee and with those of the Code of Ethics of the World Medical Association (Declaration of Helsinki).

Confidentiality of data. The authors declare that they have followed the protocols of their work center on the publication of patient data.

Right to privacy and informed consent. The authors have obtained the written informed consent of the patients or subjects mentioned in the article. The corresponding author is in possession of this document.

Conflicts of interest

The authors have no conflicts of interest to declare.

* Corresponding author.

E-mail address: milan.satendra@gmail.com (M. Satendra).

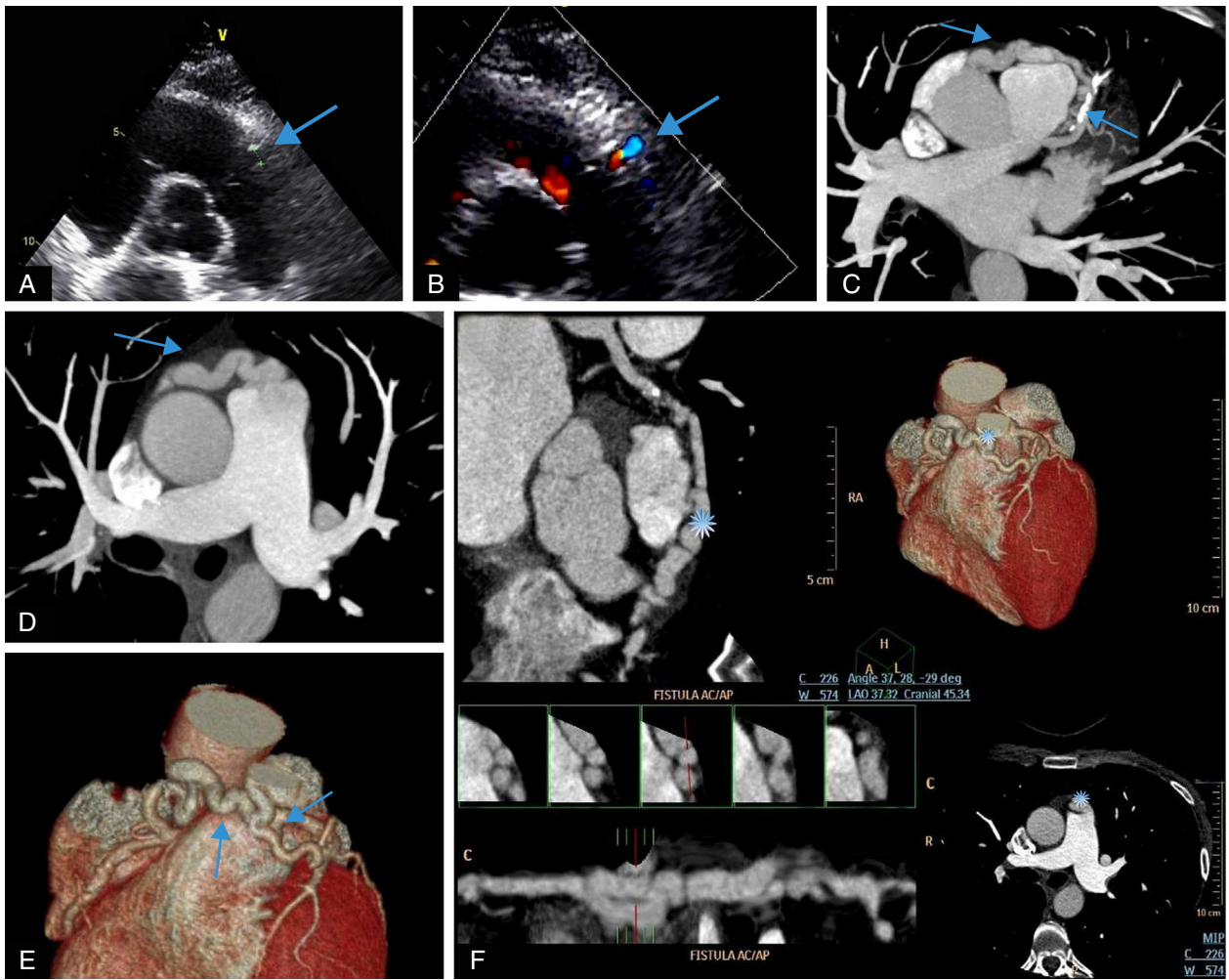


Figure 1 (A and B) Transthoracic echocardiogram and color Doppler showing tunnel-like communication (arrows). (C and D) Cross-sectional computed tomography image showing the courses of the fistulae (arrows). (E and F) Three-dimensional volume-rendered multislice multiplanar reconstruction computed tomography views showing the courses of the fistulae (arrows and asterisk).