



IMAGE IN CARDIOLOGY

Cardiac calcification: An incidental finding[☆]

Calcificação cardíaca: um achado acidental

Ana Jorge Lopes^{a,*}, Luís Ferreira Santos^b, Pedro Gama^b



^a *Unidade de Saúde Familiar Viriato, Viseu, Portugal*

^b *Serviço de Cardiologia, Centro Hospitalar Tondela-Viseu, Viseu, Portugal*

Received 9 August 2014; accepted 18 October 2014

Available online 16 March 2015

A 69-year-old man, with a history of hypertension, dyslipidemia, stroke in 1995 and left thoracic-abdominal trauma in 1999 resulting in hemopneumothorax after being hit by an ox, was referred for cardiology consultation following the incidental finding on thoracic-abdominal computed tomography (CT) of an extensive area (54 mm×36 mm×20 mm) of irregular, linear calcifications located posteriorly high in the pericardial sac (Figure 1). Transthoracic and transesophageal echocardiography and thoracic CT angiography were performed to clarify whether the calcification was intravascular or extravascular and to exclude a tumor.

The echocardiogram showed a rounded mass with calcified walls attached to and slightly compressing the left atrium and the coronary sulcus of the lateral and anterior walls, with apparent fibrocalcification of the myocardium of the basal segment of the lateral wall, which was thinner, hyperechogenic and akinetic (Figure 2). CT angiography showed the lesion high in the pericardial sac in extensive contact with the pericardium, suggesting that its epicenter was within this structure. The lesion appeared to be of

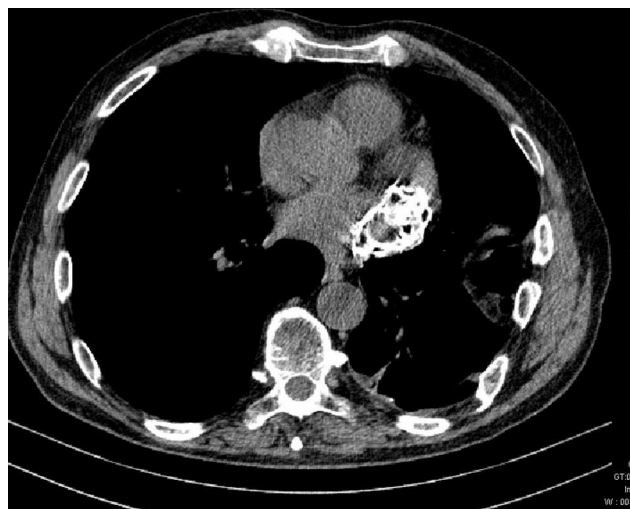

Figure 1 Thoracic computed tomogram showing a large lesion with irregular calcifications.

extravascular origin, possibly a consequence of the previous trauma (Figure 3).

The initial investigation focused on assessing the lesion, the other cardiac chambers, particularly the left atrial appendage, and the patient's hemodynamic status.

[☆] Please cite this article as: Lopes AJ, Ferreira Santos L, Gama P. Calcificação cardíaca: um achado acidental. Rev Port Cardiol. 2015;34:219–220.

* Corresponding author.

E-mail address: anaj.lopes22@gmail.com (A.J. Lopes).

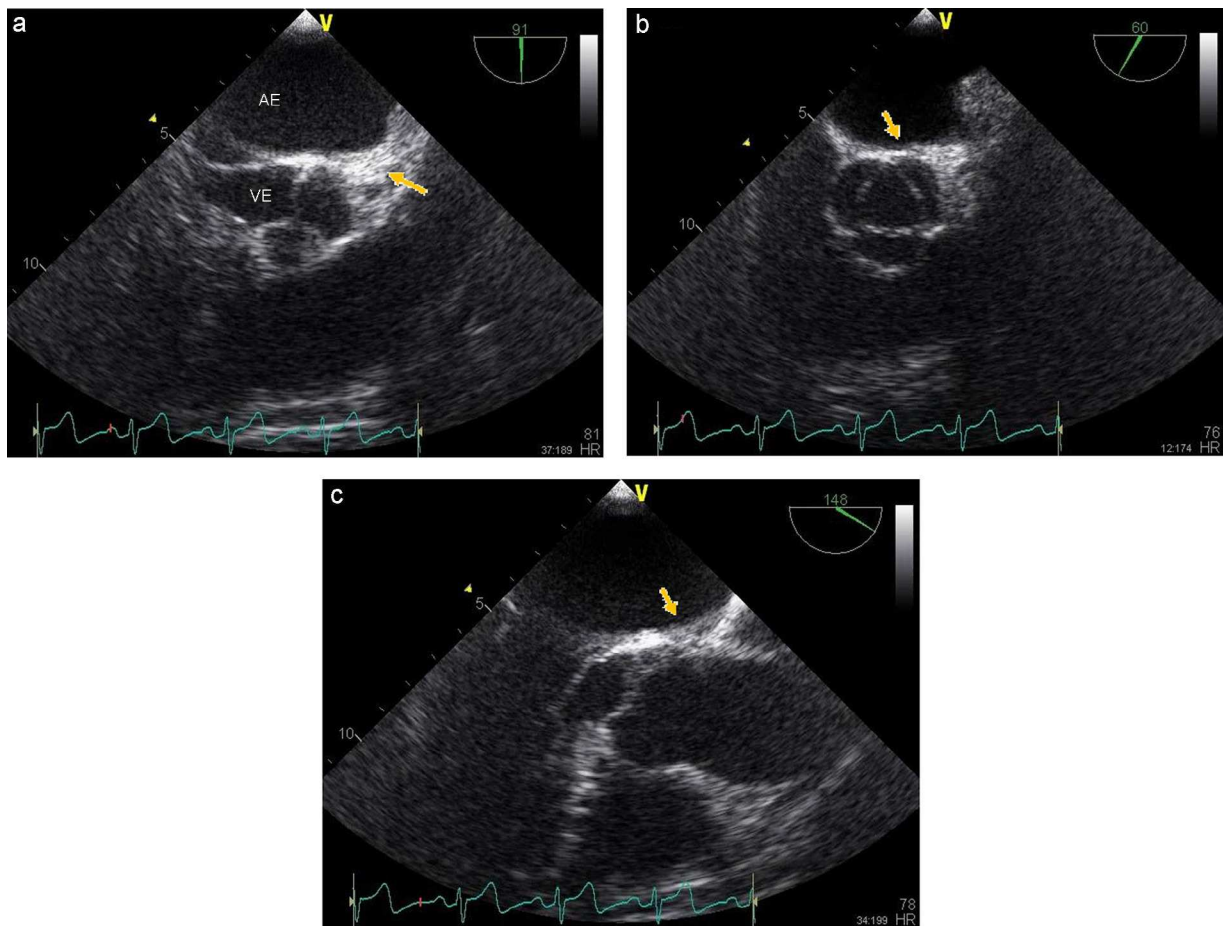


Figure 2 Echocardiogram showing the lesion. AE: left atrium; VE: left ventricle.

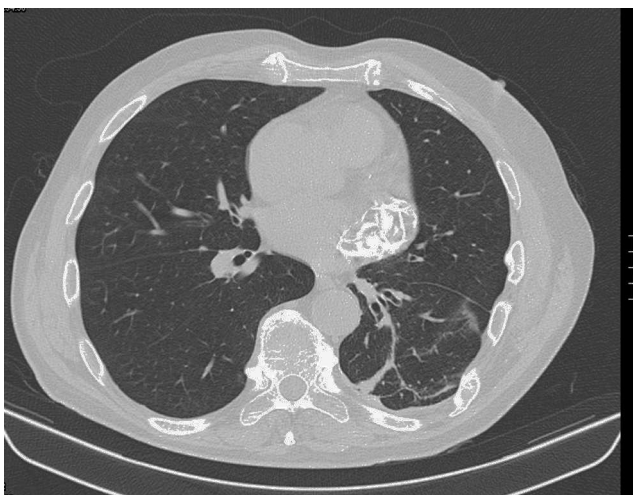


Figure 3 Thoracic computed tomography angiogram showing lesion after contrast injection.

A brief review of the literature revealed descriptions of pericardial masses, cysts and calcifications (some due to trauma), but no case with similar characteristics to the one described above.

Ethical disclosures

Protection of human and animal subjects. The authors declare that no experiments were performed on humans or animals for this study.

Confidentiality of data. The authors declare that no patient data appear in this article.

Right to privacy and informed consent. The authors declare that no patient data appear in this article.

Conflicts of interest

The authors have no conflicts of interest to declare.