

IMAGE IN CARDIOLOGY

Embolization of a Biostar device in the pulmonary artery

Embolização duma prótese Biostar na artéria pulmonar

Paolo G. Pino, Amedeo Pergolini, Giordano Zampi*

Department of Cardiovascular Science, "S. Camillo-Forlanini" Hospital, Rome, Italy

Received 31 March 2012; accepted 11 April 2012

An asymptomatic 50-year-old Caucasian woman was referred to our echocardiography laboratory to monitor a Biostar septal occluder device inserted six months before in order to close a patent foramen ovale.

On transthoracic echocardiography no residual shunt was observed but the device was not identifiable (Figure 1A); after injection of agitated saline solution in a vein of the right arm and the Valsalva maneuver, a remarkable paradoxical right-to-left shunt appeared (Figure 1B, video clip 1). The estimated systolic artery pressure was 25 mmHg.

To better understand the pathophysiology of the shunt 3D real-time transesophageal echocardiography was performed. The septal occluder was not found on the interatrial

septum (Figure 1C). A small interatrial defect was identified close to the foramen ovale (Figure 1D, video clip 2) with a trivial left-to-right shunt (Q_p/Q_s 1.1) in baseline conditions; the agitated saline contrast test after the Valsalva maneuver was markedly positive. Given the suspicion of distal embolization of the device, cardioscopy was performed: the Biostar was found in the left pulmonary artery (Figure 1E and F, video clips 3 and 4), without hemodynamic effects (mean pulmonary artery pressure 18 mmHg).

In accordance with the clinical and instrumental findings, the patient was enrolled for long-term follow-up, with regular clinical and echocardiographic monitoring in order to prevent complications.

* Corresponding author.

E-mail address: giordano.zampi@alice.it (G. Zampi).

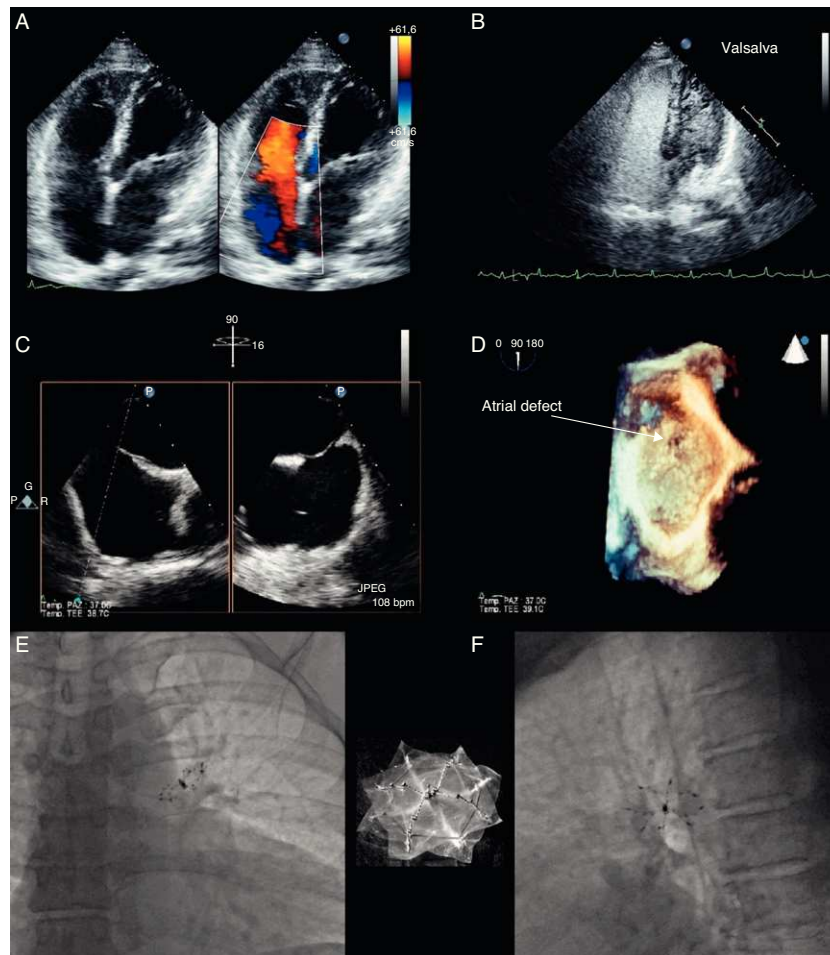


Figure 1 (A) Transthoracic echocardiography; (B) contrast echocardiography; (C) 3D real-time transesophageal echocardiography; (D) 3D off-line reconstruction of the PFO; (E and F) cardioscopy.

Ethical disclosures

Right to privacy and informed consent. The authors declare that no patient data appear in this article.

Confidentiality of data. The authors declare that no patient data appear in this article.

Protection of human and animal subjects. The authors declare that no experiments were performed on humans or animals for this investigation.

Conflicts of interest

The authors have no conflicts of interest to declare.

Appendix A. Supplementary material

Supplementary material associated with this article can be found in the online version available at [doi:10.1016/j.repc.2012.04.011](https://doi.org/10.1016/j.repc.2012.04.011).