



CASE REPORT

Right atrial aneurysm after chest trauma: Late presentation[☆]

Ninel Santos^{a,*}, Pedro Silva Cunha^a, Luísa Moura Branco^a, Ana Galrinho^a,
Ana Teresa Timóteo^a, Lídia de Sousa^a, Carlos Cota^b, Rui Cruz Ferreira^a

^a Serviço de Cardiologia, Hospital Santa Marta, Lisboa, Portugal

^b Departamento de Cardiologia, Associação Cuidados de Saúde de Portugal Telecom, Lisboa, Portugal

Received 8 April 2011; accepted 16 July 2011

Available online 13 February 2012

KEYWORDS

Aneurysm;
Right atrium;
Chest trauma;
Echocardiography;
Cardiac magnetic
resonance

Abstract We report the case of a 59-year-old patient, with a history of severe chest trauma with rib fractures at the age of 20 and recent onset of fatigue and palpitations, who was diagnosed with atrial tachycardia, which was converted pharmacologically. Cor triatriatum or Ebstein's anomaly were suspected on initial imaging studies (transthoracic echocardiography and MRI).

Due to recurrence of arrhythmia, he subsequently underwent repeat echocardiographic evaluation, which established a diagnosis of right atrial aneurysm. The arrhythmia was converted electrically. The patient has remained asymptomatic during 18 months of follow-up, without arrhythmia recurrence, medicated with carvedilol (after an initial period with amiodarone) and warfarin.

© 2011 Sociedade Portuguesa de Cardiologia. Published by Elsevier España, S.L. All rights reserved.

PALAVRAS-CHAVE

Aneurisma;
Aurícula direita;
Traumatismo
torácico;
Ecocardiografia;
Ressonância
magnética cardíaca

Aneurisma da aurícula direita após traumatismo torácico: apresentação tardia

Resumo Relata-se o caso de um paciente de 59 anos de idade, com história de traumatismo torácico grave com fractura de vários arcos costais aos 20 anos, com início recente de cansaço e palpitações, a quem foi detectada taquicardia auricular, convertida farmacologicamente. Os estudos imagiológicos (ecocardiografia transtorácica e RMN) realizados inicialmente levantaram a hipótese de se tratar de cor *triatriatum* ou anomalia de Ebstein.

Posteriormente por recorrência da arritmia, foi efectuada nova avaliação ecocardiografica transtorácica que estabeleceu o diagnóstico de aneurisma da aurícula direita. A arritmia foi convertida electricamente. Durante o seguimento de 18 meses o paciente encontra-se

[☆] Please cite this article as: Santos N. Aneurisma da aurícula direita após traumatismo torácico: apresentação tardia.

Rev Port Cardiol, 2012. doi:10.1016/j.repc.2012.01.004.

* Corresponding author.

E-mail address: ninel.gsantos@gmail.com (N. Santos).

assintomático, sem recorrência de arritmias, medicado com carvedilol (após período sob amiodarona) e varfarina.

© 2011 Sociedade Portuguesa de Cardiologia. Publicado por Elsevier España, S.L. Todos os direitos reservados.

Introduction

Atrial aneurysms are rarely encountered in cardiological practice. Most cases reported in the literature are of congenital origin and around half of patients are asymptomatic.¹ The entity was first described by Bailey² in 1955; Morrow and Behrendt performed the first surgical resection of a right atrial aneurysm in 1968.³ In 2000 Binder et al. published a review of 103 cases of atrial aneurysm (including of the coronary sinus) reported in the literature between 1955 and 1998,¹ all of which were considered to be the result of congenital malformations. Only one case has been described in Portugal.⁴

The case presented is of a right atrial pseudoaneurysm with late presentation after previous chest trauma. Only two other cases of atrial aneurysm related to chest trauma were found in a literature review, both in the right atrium (RA).

Case report

A 59-year-old man, an ex-smoker, with hypertension, dyslipidemia and obesity, was seen in the cardiology department for recent onset of fatigue on moderate exertion and palpitations. He had a history of severe chest trauma at the age of 20 with rib fractures.

The physical examination revealed arrhythmic heart sounds but no other abnormalities. The ECG showed atrial tachycardia with controlled ventricular rate, and transthoracic echocardiography led to the suspicion of right cor triatriatum. The arrhythmia was converted pharmacologically.

Cardiac magnetic resonance imaging (MRI) was subsequently performed (Fig. 1), which raised the possibility of Ebstein's anomaly or right cor triatriatum.

There was symptomatic recurrence of atrial tachycardia during follow-up despite medication with amiodarone and carvedilol. Repeat echocardiographic evaluation revealed an aneurysmal cavity in the right atrial free wall, measuring 11.8 cm × 7 cm, communicating with the atrial chamber through a 4.9 cm orifice, with no apparent tricuspid valve abnormalities (Fig. 2).

After four weeks of oral anticoagulation at therapeutic levels, intracavitary thrombi were excluded by transesophageal echocardiography, and electrical cardioversion was successfully performed. Surgical resection of the aneurysm was proposed but the patient refused. He has remained asymptomatic during 18 months of follow-up after initial presentation, in sinus rhythm, medicated with carvedilol and warfarin.

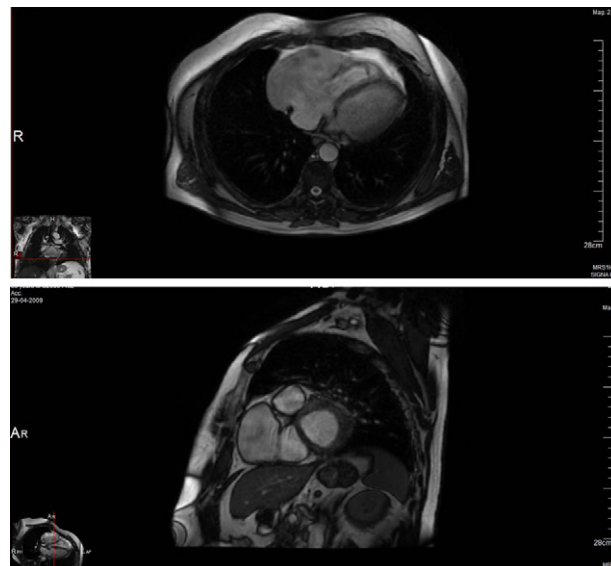


Figure 1 Cardiac magnetic resonance imaging (FIESTA), showing an anterior aneurysmal cavity in the right atrial free wall (11.2 cm × 6.6 cm) in right ventricular long-axis view (top) and in transverse view (bottom).

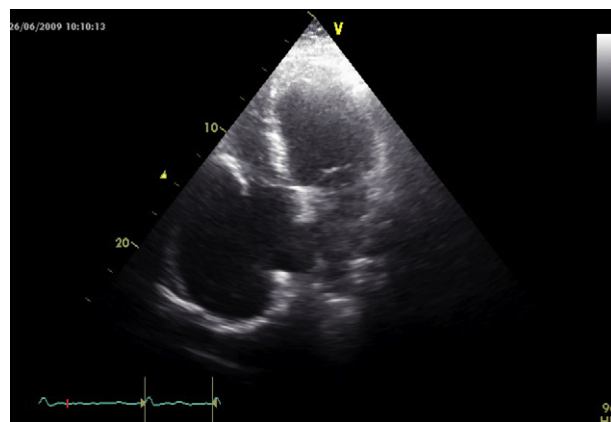


Figure 2 Transthoracic echocardiography in 4-chamber apical view, showing an aneurysmal cavity in the right atrial free wall (11.8 cm × 7 cm), communicating with the atrial chamber through a 4.9 cm orifice, with no apparent tricuspid valve abnormalities.

Discussion

Cardiac trauma most commonly causes rupture of the right ventricle, followed by the left ventricle⁵; atrial rupture is extremely rare, being caused by compressive forces

transmitted to the heart at end-systole when the atria are full and the ventricles contracted. Any compressive force on the chest or abdomen can raise pressures in the vena cava and pulmonary vasculature, which leads to a marked increase in intra-atrial pressure against the closed atrioventricular valves, directing the pressure against the thin atrial wall.⁶

We believe that in the case presented the above mechanism may have led to partial rupture of the right atrial wall, causing bleeding within the wall and formation of a pseudoaneurysm.

Right atrial aneurysms of congenital origin have been classified into four types: (1) congenital enlargement of the RA; (2) single diverticulum of the RA; (3) multiple diverticula of the RA; and (4) diverticulum of the coronary sinus.¹ Based on this classification, post-traumatic aneurysms are similar to type 2 (single diverticulum).

As with atrial aneurysms of congenital origin, our case presented as supraventricular arrhythmia, as did the other two cases of post-traumatic aneurysm described in the literature – one with atrial flutter⁷ and the other with atrial fibrillation and signs of heart failure.⁶

Diagnosis can be made by transthoracic or transesophageal echocardiography, MRI or computed tomography, which in some cases are prompted by an incidental finding of cardiomegaly on the chest X-ray of an asymptomatic patient.⁸

Diagnosing atrial aneurysms is often difficult, initial diagnostic hypotheses including Ebstein's anomaly, tumor, pericardial effusion and pericardial cyst. In the case presented, initial hypotheses were cor triatriatum or Ebstein's anomaly. The definitive diagnosis was made by transthoracic echocardiography after MRI suggested Ebstein's anomaly.

The rarity of post-traumatic atrial aneurysm means that its prognosis has not been established. Corrective surgery was performed in the two previous cases, but Binder et al. reported that only 38% of patients with congenital aneurysms underwent surgical treatment. Even in the absence of arrhythmias, anticoagulation is recommended due to the risk of thromboembolism.¹

Conflicts of interest

The authors have no conflicts of interest to declare.

References

1. Binder TM, Rosenhek R, Frank H, et al. Congenital malformations of the right atrium and the coronary sinus: an analysis based on 103 cases reported in the literature and two additional cases. *Chest*. 2000;117:1740–8.
2. Bailey CP. *Surgery of the heart*. Philadelphia, PA: Lea and Febiger; 1955. p. 413.
3. Morrow AG, Behrendt DM. Congenital aneurysm (diverticulum) of the right atrium: clinical manifestations and results of operative treatment. *Circulation*. 1968;38:124–8.
4. Afonso PV, Antunes MJ. Aneurisma da Aurícula Direita – Caso clínico. *Rev Port Cardiol*. 2007;26:1049–52.
5. Parmley LF, Manoin WC, Mattingly TW. Non-penetrating traumatic injury of the heart. *Circulation*. 1958;18:571–96.
6. Vonder Emde J, Cesjevar RA, Kretschmer S, et al. Post traumatic aneurysm of right atrium. *Ann Thorac Surg*. 1996;62:1507–9.
7. Kumar R, Khandekar J, Khandeparkar J. Atrial flutter with right atrial aneurysm – late presentation of cardiac trauma – case report. *Indian J Thorac Cardiovasc Surg*. 2005;21:222–3.
8. Yoon J-W, Kim H-J, Lee S-H, et al. A case of right atrial aneurysm incidentally found in old age. *J Cardiovasc Ultrasound*. 2009;17:96–8.