


Journal Pre-proof

A Holy Situation: An Unexpected Complication During a TAVI Procedure

Inês Ferreira Neves Tiago Mendonça Ruben Ramos



PII: S0870-2551(25)00117-9

DOI: <https://doi.org/doi:10.1016/j.repc.2025.01.004>

Reference: REPC 2428

To appear in: *Revista Portuguesa de Cardiologia*

Received Date: 22 January 2025

Accepted Date: 29 January 2025

Please cite this article as: Neves IF, Mendonça T, Ramos R, A Holy Situation: An Unexpected Complication During a TAVI Procedure, *Revista Portuguesa de Cardiologia* (2025), doi: <https://doi.org/10.1016/j.repc.2025.01.004>

This is a PDF file of an article that has undergone enhancements after acceptance, such as the addition of a cover page and metadata, and formatting for readability, but it is not yet the definitive version of record. This version will undergo additional copyediting, typesetting and review before it is published in its final form, but we are providing this version to give early visibility of the article. Please note that, during the production process, errors may be discovered which could affect the content, and all legal disclaimers that apply to the journal pertain.

© 2025 Published by Elsevier España, S.L.U. on behalf of Sociedade Portuguesa de Cardiologia.

Article type: Snapshot

Title: A Holy Situation: An Unexpected Complication During a TAVI Procedure

Title in portuguese: Uma Complicação Inesperada Durante um Procedimento de TAVI

Authors: Inês Ferreira Neves¹, Tiago Mendonça¹, Ruben Ramos¹

¹Department of Cardiology, Hospital de Santa Marta, Centro Hospitalar Universitário de Lisboa Central, ULS S. José, Lisbon, Portugal.

Caso clínico vencedor do Prémio Jovem Cardiologista de Intervenção 2024 na categoria de intervenção estrutural.

Corresponding Author

Inês Ferreira Neves

Address: Rua de Santa Marta, n. 50

1169-024 Lisbon, Portugal

Telephone: +351912699482

E-mail: inessferreiraneves@gmail.com

An 86-year-old male patient underwent transcatheter aortic valve implantation (TAVI) for severe aortic stenosis, having presented with syncope. His past medical history was relevant for dyslipidemia, right bundle branch block, chronic kidney disease and peripheral artery disease.

Prior to the procedure, an echocardiography showing a peak velocity in aortic valve of 5 m/s, with mean pressure gradient of 69 mmHg and an area of valve of 0.95 cm² and a computerized tomography (CT) scan demonstrating a tricuspid aortic valve of 24.9 mm diameter according to 78.2 mm perimeter of aortic annulus had been performed. Valvular calcium score was 3645, with a valvular area of 0.8 cm². A severe calcification of the aortic arch was also noted in the CT scan (Figure 1 A-C).

A SAPIEN 3 ULTRA 26 mm was implanted (supplemental video 1). Pre-dilation was performed with a valve balloon dilated to 22 mm. After the implantation of the valve, a moderate residual leak was noted (Supplemental videos 2 and 3). Post-dilation with the same balloon was attempted, encountering difficulty with balloon progression (Supplemental video 4). At this time, the patient presented with hemodynamic collapse and cardiac arrest. Echocardiogram showed no pericardial effusion, excluding annular rupture, and the coronary arteries were patent. While performing advanced life support maneuvers, an aortography was performed, revealing a rupture at the transition between the aortic arch and the descending aorta (Figure 2, Supplemental video 5). Tamponade with a 28 mm balloon was performed and a TEVAR 28 mm was implanted with subsequent dilation using a RELIANT balloon. While resolution of the active rupture was achieved angiographically (Figure 3, supplemental videos 6-8), and despite 55 minutes of resuscitation maneuvers, cardiac rhythm could not be restored.

Aortic rupture is a rare complication of TAVI, occurring in <1% of the procedures, but it is generally catastrophic.^{1,2} Rupture can occur from puncture of the aorta by the delivery catheter when trying to advance around an acute angulation in a tortuous aorta.² A high level of suspicion is needed, and the diagnosis should be considered in any patient undergoing TAVI who experiences hemodynamic instability.^{1,2} It is a life-threatening complication, as it causes rapid onset of hemorrhagic shock. Management options include surgical or endovascular repair (with covered stent grafts).² Despite appropriate interventions, mortality remains high.^{1,2}

We declare that there is no funding for this work and none of the authors have conflicts of interest to disclose.

Ethics in publishing

1. Does your research involve experimentation on animals?:

No

2. Does your study include human subjects?:

No

3. Does your study include a clinical trial?:

No

4. Are all data shown in the figures and tables also shown in the text of the Results section and discussed in the Conclusions?:

Yes

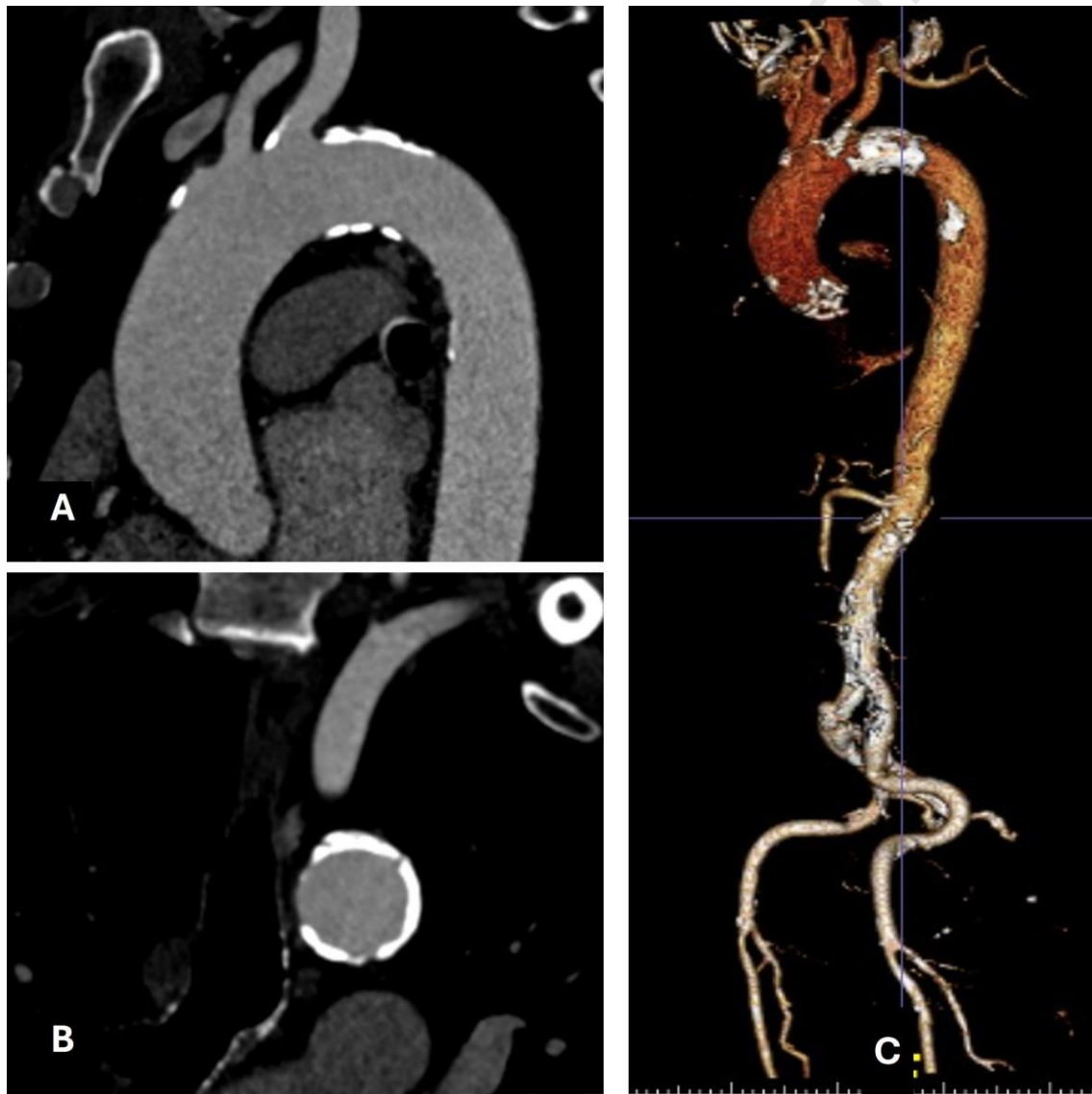
Journal Pre-proof

References:

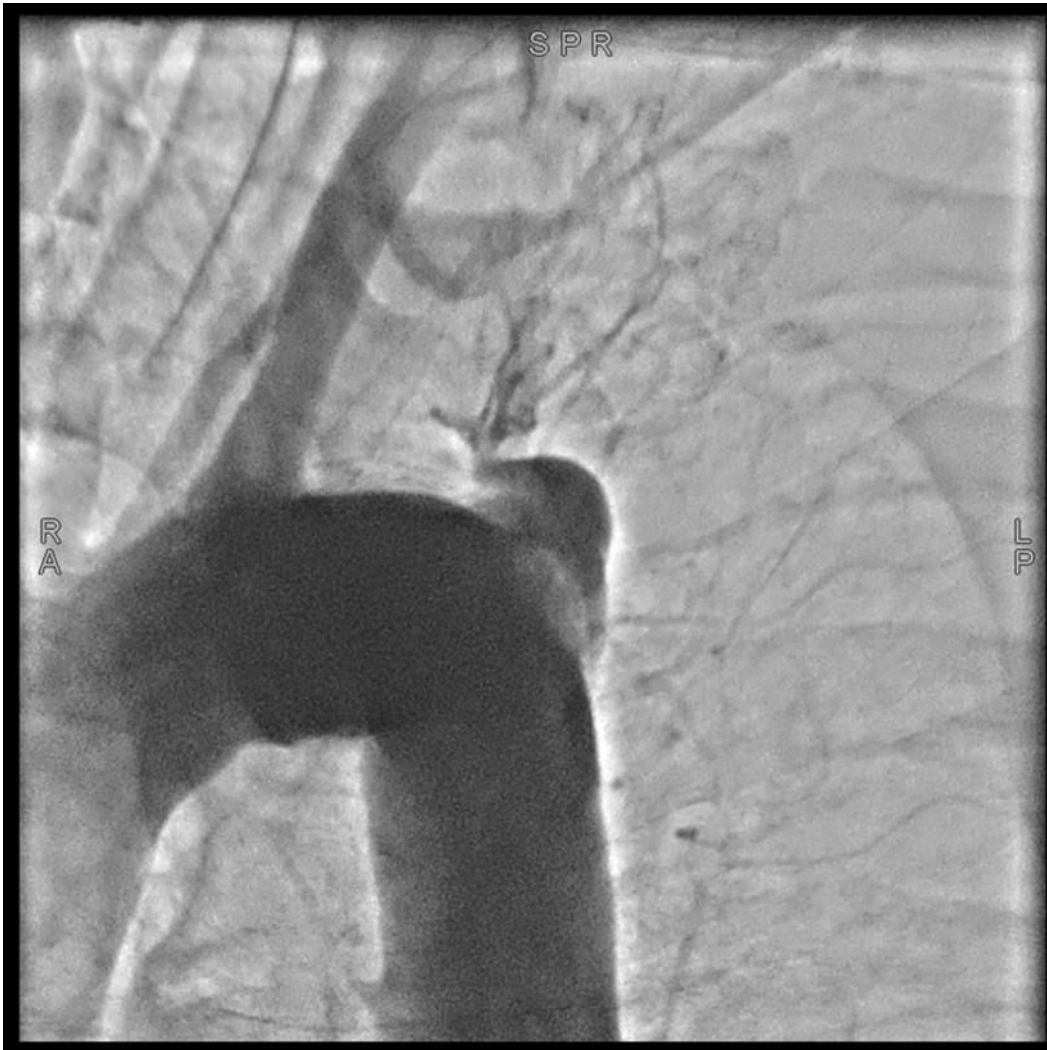1. Mangla A, Gupta S. Vascular complications post-transcatheter aortic valve procedures. *Indian Heart J.* 2016;68(5):724-731. doi:10.1016/J.IHJ.2015.11.024
2. Coughlan JJ, Kiernan T, Mylotte D, et al. Annular rupture during transcatheter aortic valve implantation: Predictors, management and outcomes. *Interv Cardiol Rev Res Resour.* 2018;13(3):140-144. doi:10.15420/icr.2018.20.2

Figure legends:

- Figure 1 (A-C): calcification of the aortic arch in the CT scan.



- Figure 2: Aortic rupture at the transition between the arch and the descending aorta



- Figure 3: Angiographic resolution with a TEVAR 28 mm.

