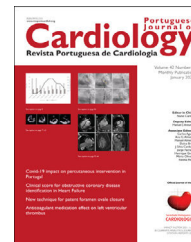




Revista Portuguesa de  
**Cardiologia**  
Portuguese Journal of **Cardiology**  
[www.revportcardiol.org](http://www.revportcardiol.org)



## EDITORIAL COMMENT

# Enhancing diagnostic yield in MINOCA: The critical timing of cardiac magnetic resonance

## Otimizar a rentabilidade diagnóstica no doente com suspeita de MINOCA: a importância do *timing* da ressonância magnética cardíaca

Rita Faria

Department of Cardiology, Gaia Hospital Center, Vila Nova de Gaia, Portugal

The recent publication of 'Early *versus* late cardiac magnetic resonance in the diagnosis of MINOCA'<sup>1</sup> deserves our attention and should prompt a reflection on access to cardiac magnetic resonance (CMR) in Portugal. This retrospective study evaluated the diagnostic performance of CMR in patients with an initial diagnosis of myocardial infarction with nonobstructive coronary arteries (MINOCA). A total of 163 patients who were assessed with CMR within 180 days of hospital admission were included.

The authors concluded that CMR is a pivotal method to obtain the correct diagnosis in three of each four patients (high reclassification rate), with myocardial infarction being confirmed in 31% of patients. This number could be more impressive if parametric mapping techniques were available at the time. These findings align with the results of other studies, including a larger retrospective study published by Liang et al.<sup>2</sup>

A noteworthy, but expected, finding was that the median time between hospital admission and CMR was significantly shorter in groups with a diagnosis compared to the group without a diagnosis ( $p=0.038$ ). Additionally, the diagnostic yield of CMR was significantly higher when performed within 14 days of admission ( $p=0.022$ ).

Not only do the paper offers valuable insights into the role of CMR in patients with suspected MINOCA according to current recommendations,<sup>3–5</sup> but more importantly it gives us a perspective on local practices and resources – of 516 patients with suspected MINOCA '331 did not undergo CMR and 22 patients had CMR>180 days after', enhancing the need for improved and faster access to CMR in Portugal.

The authors also delved into a new aspect by examining how CMR plays a role in the prognosis of individuals suspected of having MINOCA. In the short 12-month follow-up, suspected MINOCA was associated with good prognosis and low-mortality. However, a confirmed diagnosis of MINOCA via CMR was associated with a greater propensity for developing heart failure. In a recent systematic review and meta-analysis from Mileva et al.,<sup>6</sup> a confirmed diagnosis of MINOCA through CMR correlated with a 2.4-fold increase in the risk of major adverse cardiovascular events.

Despite the considerable morbidity associated with MINOCA, significant gaps in evidence persist regarding treatment strategies and the subsequent impact on prognosis. Notably, a recent review by Alves da Silva et al.<sup>7</sup> presented a comprehensive diagnostic algorithm and cause-targeted treatment framework for these patients, underscoring the key role of CMR.

In conclusion, this well written study enhances the optimal timing of CMR in suspected MINOCA and the importance of early imaging to identify underlying etiologies. I commend the authors for their valuable contribution, shedding light on

E-mail address: [rita.d.faria@gmail.com](mailto:rita.d.faria@gmail.com)

<https://doi.org/10.1016/j.repc.2024.05.007>

0870-2551/© 2024 Published by Elsevier España, S.L.U. on behalf of Sociedade Portuguesa de Cardiologia. This is an open access article under the CC BY-NC-ND license (<http://creativecommons.org/licenses/by-nc-nd/4.0/>).

Please cite this article as: Faria R, Enhancing diagnostic yield in MINOCA: The critical timing of cardiac magnetic resonance, Revista Portuguesa de Cardiologia, <https://doi.org/10.1016/j.repc.2024.05.007>

the limitations in accessing a crucial diagnostic tool such as CMR that we encounter in our daily practice.

### Conflict of interest

None.

### References

1. Conde IM, Salazar M, Pereira VH, et al. Early versus late cardiac magnetic resonance in the diagnosis of MINOCA. *Rev Port Cardiol.* 2024;43, <http://dx.doi.org/10.1016/j.repc.2023.12.010>.
2. Liang K, Bisaccia G, Leo I, et al. CMR reclassifies the majority of patients with suspected MINOCA and non-MINOCA. *Eur Heart J Cardiovasc Imaging.* 2024;25:8–15.
3. Tamis-Holland JE, Jneid H, Reynolds HR, et al. Contemporary diagnosis and management of patients with myocardial infarction in the absence of obstructive coronary artery disease: a scientific statement from the American Heart Association. *Circulation.* 2019;139:E891–908.
4. Agewall S, Beltrame JF, Reynolds HR, et al. ESC working group position paper on myocardial infarction with non-obstructive coronary arteries. *Eur Heart J.* 2017;38:143–53.
5. Collet J-P, Thiele H, Barbato E, et al. 2020 ESC Guidelines for the management of acute coronary syndromes in patients presenting without persistent ST-segment elevation: the Task Force for the management of acute coronary syndromes in patients presenting without persistent ST-segment elevation of the European Society of Cardiology (ESC). *Eur Heart J.* 2020;42:1289–367.
6. Mileva N, Paolisso P, Gallinoro E, et al. Diagnostic and prognostic role of cardiac magnetic resonance in MINOCA: systematic review and meta-analysis. *JACC Cardiovasc Imaging.* 2023;16:376–89.
7. Alves da Silva P, Bucciarelli-Ducci C, Sousa A. Myocardial infarction with non-obstructive coronary arteries: etiology, diagnosis, treatment and prognosis. *Enfarte agudo do miocárdio sem obstrução das artérias coronárias: etiologia, diagnóstico, tratamento e prognóstico.* *Rev Port Cardiol.* 2023;42:655–66.