



IMAGE IN CARDIOLOGY

A rare case of cardiac arrest due to anomalous origin of the non-dominant right coronary artery

Um caso raro de paragem cardiorrespiratória associado a origem anómala da artéria coronária direita não dominante

Pedro Carvalho^{a,*}, Diana Carvalho^a, Lisa Ferraz^a, Ricardo Ladeiras Lopes^b, Ana Briosa Neves^a



^a *Cardiology Department, Centro Hospitalar do Baixo Vouga, Cardiology Department, Centro Hospitalar do Baixo Vouga, Aveiro, Portugal*

^b *Cardiology Department, Centro Hospitalar do Baixo Vouga, Cardiology Department, Centro Hospitalar Vila Nova de Gaia/Espinho, Vila Nova de Gaia, Portugal*

Received 8 August 2021; accepted 26 August 2021
 Available online 10 June 2022

A 29-year-old male had a cardiac arrest while running on the treadmill. The initial rhythm was ventricular fibrillation and he was successfully resuscitated. The patient had been performing leisure exercise for years and reported no symptoms prior to collapsing. He had no family history of cardiac disease or sudden death. He was not taking medication and denied substance abuse.

The electrocardiogram and echocardiogram were normal. Cardiac troponin I was elevated, peaking 24 hours later at 20 515 pg/ml. Coronary angiography revealed anomalous origin of the non-dominant right coronary artery (RCA) from the left sinus of Valsalva. Computed tomography coronary angiography (CTCA) confirmed several high-risk features: slit-like orifice, acute takeoff, and

interarterial and intramural course (Figure 1A-D). Cardiac magnetic resonance imaging showed absence of late gadolinium enhancement. Due to the rarity of cardiac arrest associated with non-dominant RCA abnormalities, genetic testing was carried out, which was negative for channelopathies.

The patient underwent cardiac surgery for unroofing of the RCA. He was discharged on aspirin and beta-blockers. Exercise electrocardiography performed three months later revealed no ischemia or arrhythmias. CTCA confirmed corrected origin of the RCA with no ostial stenosis (Figure 1E and F) so he was cleared to resume leisure exercise.

Anomalous coronary artery origin is a common cause of cardiac arrest in young athletes, particularly in cases of an

* Corresponding author.

E-mail address: carvalho.pmt@gmail.com (P. Carvalho).

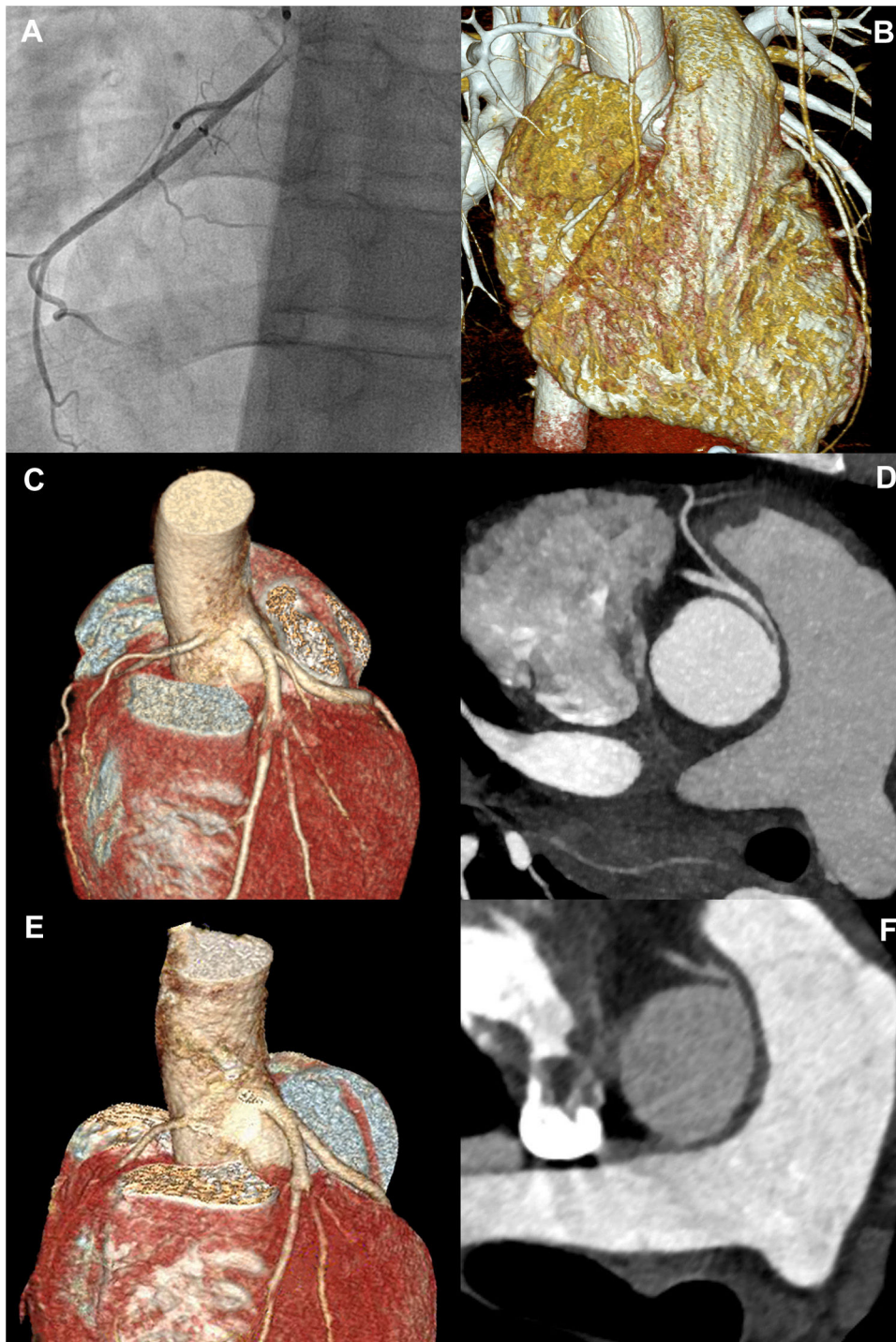


Figure 1 Coronary imaging, including preoperative invasive coronary angiography of the right coronary artery (A); computed tomography coronary angiography volume rendering (B and C) and multiplanar reformatting (D) and postoperative computed tomography coronary angiography volume rendering (E) and multiplanar reformatting (F). Coronary imaging revealed an anomalous origin of the non-dominant right coronary artery from the left sinus of Valsalva, with a slit-like orifice, acute takeoff and an interarterial and intramural course. Postoperative imaging confirmed corrected origin of the right coronary artery without residual stenosis.

anomalous left coronary artery, presumably due to more at-risk myocardium. A cardiac arrest caused by an anomalous non-dominant RCA is a rare event only seldom reported in the scientific literature.

Conflicts of interest

The authors have no conflicts of interest to declare.