



LETTER TO THE EDITOR

Focus on spontaneous coronary artery dissection: Where are we now?



Foco na disseção espontânea da artéria coronária: Onde estamos agora?

Dear Editor,

I read with great interest the single-center experience on spontaneous coronary artery dissection (SCAD) recently published by Abreu and colleagues in this journal.¹ The authors reported a case series consisting of 27 patients, admitted to the cardiology department between January 2010 and December 2016, with a diagnosis of acute coronary syndrome (ACS) due to ongoing SCAD.

The prevalence of SCAD was 0.5% among patients who underwent catheterization for suspected ACS (15 NSTEMI, 10 STEMI and two sudden cardiac arrest). Most were women (22 F:5 M) and the cohort's median age was 56±11 years.

Patient characteristics and clinical presentation with predisposing factors were reported in Table 1 of the article. They were managed mainly in a conservative manner (15 medical therapy vs. 12 PCI). It is not insignificant that four of the 15 patients managed conservatively had a myocardial infarction on follow-up and in two of these the initial treatment was modified, requiring a switch to coronary angioplasty, with no cases of stent thrombosis at follow-up. A close clinical follow-up with optical coherence tomography (OCT) for PCI-managed cases was recommended. Prognosis was good despite the high prevalence of reinfarction in-hospital or during follow-up.

Considering the high level of interest in this subject, the European Society of Cardiology, in partnership with the Acute Cardiovascular Care Association, has established a European SCAD registry as a platform for collaborative research with the aim of improving awareness of the condition for better management.

Here I would like to put forward some food for thought that could be useful and interesting for the *Journal's* readers.

Of note, Abreu et al. remarked that SCAD is still an underestimated entity due to the challenging diagnosis, in which a high degree of clinical suspicion plays a key role. In this regard, I would like to underline that emerging evidence shows that this underestimation is mainly due to the absence of the classic angiographic hallmarks, which are lacking in >70% of angiographies² and may be discovered only by intravascular imaging, namely OCT and intravascular ultrasound (IVUS).^{2,3}

Considering the high rate of misdiagnosed SCAD,^{2–6} an interesting and useful score system (Figure 1) was previously published and tested^{6–8} allowing interventionists to select suspected cases in which intravascular imaging, particularly OCT, as the first choice, thanks to its higher spatial resolution (about 10 times greater than IVUS, which represents the second line) could identify the presence of SCAD, thus reducing the time to obtain the correct diagnosis and initiate appropriate therapy. The score is in the process of statistical validation on a larger cohort.

Moreover, SCAD management remains challenging because of the lack of evidence supporting standard medical therapy, and the role of percutaneous or surgical revascularization is strongly debated.^{4,5,9} Abreu et al. state that, when necessary, a long stent or two stents were implanted, preventing the extension of intramural hematoma caused by stent compression against the vessel wall.

Conservative management (medical therapy) with aspirin, P2Y₁₂ inhibitors, beta-blockers and statins is the preferred option according to a recently published experience-based survey. Alternatively, our group suggested invasive treatment with implantation of a drug-eluting stent or a bioresorbable scaffold (BRS) in cases of dissection involving vessels of ≥3 mm diameter or proximal vessel segments.⁷

In my opinion, and following our experience^{6–8,10,11} and the recent literature,^{12,13} these patients are eligible for bioresorbable scaffolding that allows vessel sealing, in consideration of the typical absence of atherosclerotic plaque rupture and the young age of most subjects affected, as in the cases reported, thus avoiding a permanent metal prosthesis.

In conclusion, our clinical-angiographic score could have helped provide the correct diagnosis, especially in challenging cases, thus allowing effective therapy that in my opinion should have been invasive, preferably with BRS

DOI of original article: <https://doi.org/10.1016/j.repc.2017.07.019>

<https://doi.org/10.1016/j.repc.2018.08.005>

0870-2551/© 2018 Sociedade Portuguesa de Cardiologia. Published by Elsevier España, S.L.U.

This is an open access article under CC BY-NC-ND license. (<http://creativecommons.org/licenses/by-nc-nd/4.0/>)

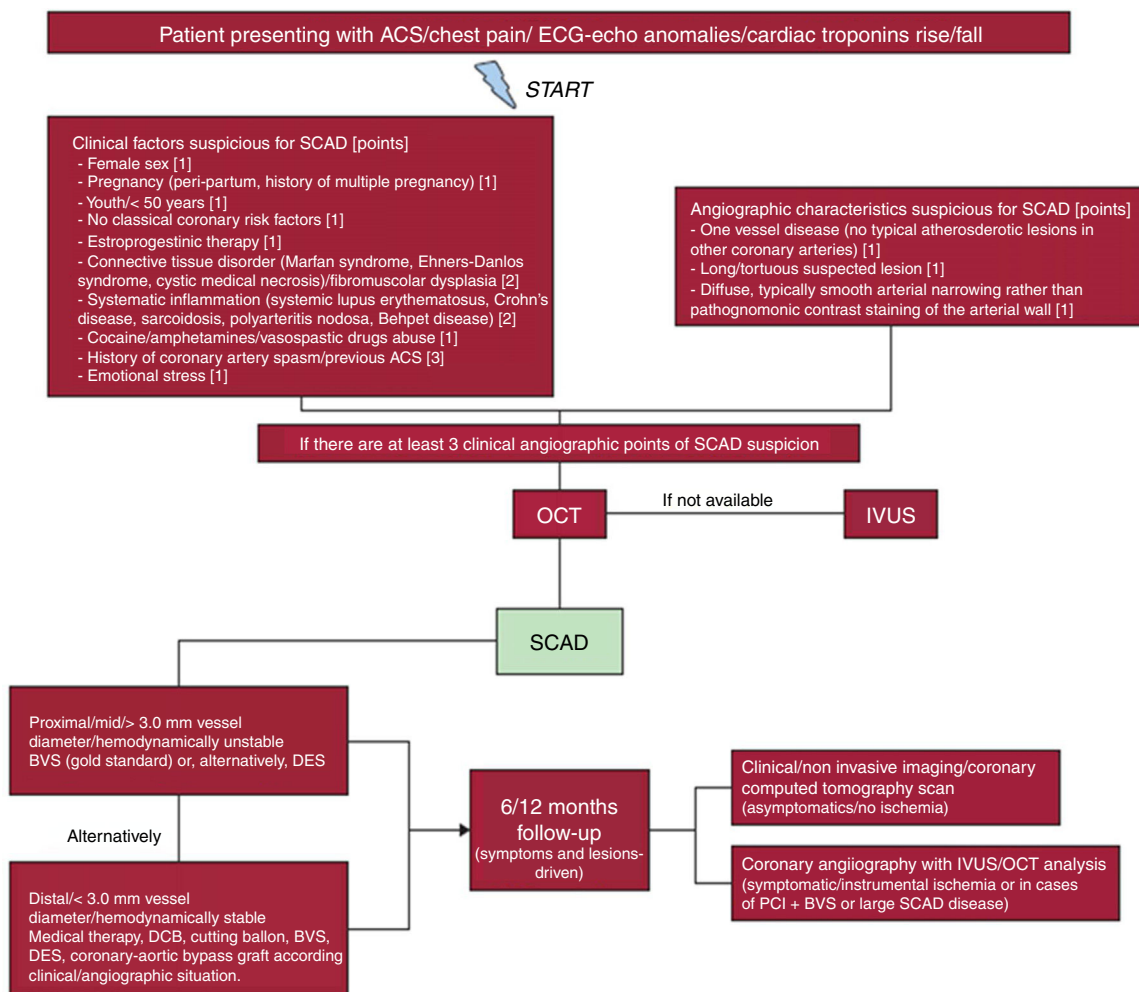


Figure 1 Flowchart for the diagnosis and management of spontaneous coronary artery dissection.⁷

implantation, considering the clinical presentation of ACS and for lesions longer than 3 mm or involving the proximal segment of coronary arteries, in view of the risk of potentially life-threatening complications that could have occurred in young people like the patients of the case series reported.

Conflicts of interest

The author has no conflicts of interest to declare.

References

1. Abreu G, Galvão Braga C, Costa J, et al. Spontaneous coronary artery dissection: a single-center case series and literature review. *Rev Port Cardiol.* 2018;37:707–13.
2. Saw J, Mancini GBJ, Humphries K, et al. Angiographic appearance of spontaneous coronary artery dissection with intramural hematoma proven on intracoronary imaging. *Catheter Cardiovasc Interv.* 2016;87:E54–61.
3. Alfonso F, Paulo M, Gonzalo N, et al. Diagnosis of spontaneous coronary artery dissection by optical coherence tomography. *J Am Coll Cardiol.* 2012;59:1073–9.
4. Yip A, Saw J. Spontaneous coronary artery dissection – a review. *Cardiovasc Diagn Ther.* 2015;5:37–48.
5. Saw J, Mancini GB, Humphries KH. Contemporary review on spontaneous coronary artery dissection. *J Am Coll Cardiol.* 2016;68:297–312.
6. Buccheri D, Piraino D, Latini RA, et al. Spontaneous coronary artery dissections: a call for action for an underestimated entity. *Int J Cardiol.* 2016;214:333–5.
7. Buccheri D, Piraino D, Andolina G. Score system approach to diagnose and manage spontaneous coronary artery dissection. *Rev Esp Cardiol.* 2016;69:878–9.
8. Buccheri D, Piraino D, Cortese B. Intravascular imaging as a tool for definite diagnosis of acute coronary syndrome caused by spontaneous coronary artery dissection. *Int J Cardiol.* 2016;214:43–5.
9. Quadri G, Cerrato E, Escaned J, et al. Importance of close surveillance of patients with conservatively managed spontaneous coronary artery dissection. *JACC Cardiovasc Interv.* 2018;11:e87–9.
10. Buccheri D, Zambelli G, Alfonso F, et al. Pulse on spontaneous coronary artery dissections: experience-based survey. *JACC Cardiovasc Interv.* 2017;10:1469–71.
11. Buccheri D, Zambelli G. Focusing on spontaneous coronary artery dissection: actuality and future perspectives. *J Thorac Dis.* 2016;8:E1784–6.

12. Ielasi A, Cortese B, Tarantini G, et al. Sealing spontaneous coronary artery dissection with bioresorbable vascular scaffold implantation: data from the prospective "Registro Absorb Italiano" (RAI Registry). *Int J Cardiol.* 2016;212:44–6.
13. Quadri G, Tomassini F, Cerrato E, et al. First reported case of magnesium-made bioresorbable scaffold to treat spontaneous left anterior descending coronary artery dissection. *Catheter Cardiovasc Interv.* 2017;90:768–72.

Dario Buccheri

*Interventional Cardiology, "S. Antonio Abate" Hospital,
Via Cosenza, 80, 91016 Erice (TP), Italy
E-mail address: dariobuccheri@gmail.com*