



EDITORIAL COMMENT

Right atrial function with speckle tracking echocardiography: Do we really need it?



Função da aurícula direita com ecocardiografia de *speckle tracking*: precisamos realmente desse processo?

Lígia Mendes^{a,*}, Nuno Cardim^b

^a Cardiology, Hospital da Luz, Setúbal, Portugal

^b Cardiac Multimodality Imaging Department, Hospital da Luz, Lisbon, Portugal

Available online 10 December 2017

Atrial septal defect (ASD) is one of the most common congenital cardiac anomalies presenting in adulthood. ASD is characterized by a defect in the interatrial septum that allows pulmonary venous return from the left atrium to pass directly to the right atrium. The magnitude of the left-to-right shunt across the ASD depends on the defect size, the relative compliance of the ventricles, and the relative resistance of both the pulmonary and the systemic circulation.

The three major types of atrial septal defect (ostium secundum, ostium primum and sinus venosus) account for 10% of all congenital heart defects and as much as 20-40% of congenital heart disease presenting in adulthood.

In general, elective closure is recommended for all ASDs with evidence of right ventricular (RV) overload or with a clinically significant shunt (pulmonary flow [Qp] to systemic flow [Qs] ratio >1.5). Lack of symptoms is not a contraindication for repair.¹ At any age, ASD closure is followed by symptomatic improvement and regression of RV size.²

Ostium secundum ASD may be closed with a variety of catheter-implanted occlusion devices rather than by direct surgical closure with cardiopulmonary bypass.³ Compared

with surgery, transcatheter closure appears to have additional benefits, including hemodynamic improvement and preservation of atrial function.⁴

Although myocardial mechanics has been primarily used to study left ventricular (LV) performance, since 2007 it has also been applied to the assessment of thin-walled structures such as the left atrium.⁵ Subsequently, analysis of right atrial (RA) mechanics using two-dimensional (2D) speckle tracking echocardiography (STE) also proved feasible,⁶⁻¹² and normal reference values have been published.^{13,14}

Throughout the phases of the cardiac cycle, the right atrium serves three distinct functions (Figure 1):

- Reservoir phase: storage of blood arriving from the systemic venous circuit during ventricular systole;
- Conduit phase: passive filling of blood from the inferior and superior venae cavae to the right ventricle during early and mid diastole;
- Booster pump phase: contributing to RV filling in late diastole by atrial contraction.

The reservoir and conduit phases are often termed passive phases, whereas the atrial contraction phase is considered the active phase. All phases are modulated by loading conditions, heart rate and the intrinsic contractility of the atria.¹⁵

DOI of original article: <http://dx.doi.org/10.1016/j.repc.2017.06.013>

* Corresponding author.

E-mail address: ligia.mendes@hospitaldaluz.pt (L. Mendes).

<https://doi.org/10.1016/j.repc.2017.11.008>

0870-2551/© 2017 Sociedade Portuguesa de Cardiologia. Published by Elsevier España, S.L.U. All rights reserved.

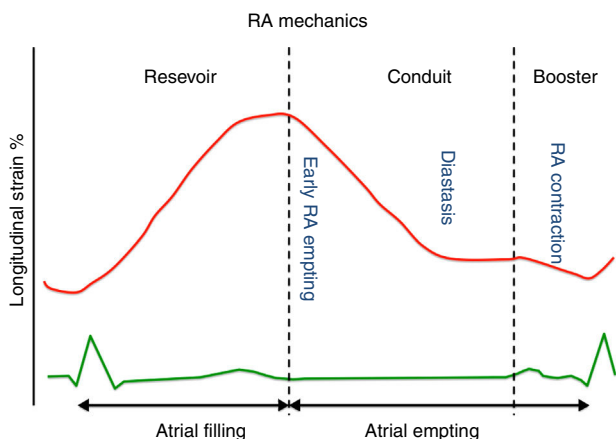


Figure 1 Longitudinal Strain Curve during the different phases of the cardiac cycle.

Right atrial peak strain derived from 2D-STE has been proved to be a reliable tool to study RA performance.¹⁶ Peak atrial strain (the peak of the positive deflection occurring during the reservoir phase, when the right ventricle contracts and the right atrium fills against a closed tricuspid valve) is perhaps the most used parameter of RA function. It depends on:

- Long-axis ventricular contraction¹⁷ – higher longitudinal RV strain results in greater tricuspid annular plane systolic excursion (TAPSE) during systole and therefore higher RA strain (Figure 2);
- RA compliance¹⁷ – less compliant atria have lower strain;
- RA volume¹⁸ – for the same amount of blood received, dilated atria have lower peak atrial strain than non-dilated atria (Figure 3).

In accordance with the above, since a chronic significant left-to-right shunt through an ASD leads to a varying degree of RA dilatation due to volume overload, peak atrial strain should be decreased in ASD patients, who have dilated atria. However, in the absence of pulmonary hypertension, it should be increased, due to high TAPSE in the presence of increased preload.

In this issue of the *Journal*, Ozturk et al.¹⁹ show that 2D-STE-derived RA peak strain is decreased in ASD patients and increases after ASD closure – a similar result to those of another group²⁰ who used a different methodology (strain derived from tissue Doppler imaging) to demonstrate low peak RA strain before ASD closure.

As pointed out above, RA strain partially depends on RV systolic function and on TAPSE; so as expected, in the study by Ozturk et al.,¹⁹ as TAPSE was low, RA peak strain was also low before closure, and both increased after the procedure.

Why was TAPSE decreased before ASD closure, in the presence of a significant ASD with volume overload? The answer probably lies in the high pulmonary artery systolic pressure (PASP) found in Ozturk et al.'s study¹⁹ (mean PASP 51.4±16.3 mmHg), which decreases RV systolic performance (as shown by TAPSE) and consequently RA peak strain. In fact, in a previous study by Jategaonkar et al.,²¹ also with ASD patients but without pulmonary hypertension (mean PASP 19.9±5.2 mmHg), both TAPSE and RV strain decreased after ASD closure.

To conclude, do we really need peak RA strain, it is methodologically complex and difficult to interpretation, when there are simpler and more reproducible measures such as TAPSE (or RV strain)? And do we really need to study the atria with 2D-STE, a cutting-edge technique with great potential in different clinical scenarios, but posing demanding technical challenges for RA assessment (thin walls, difficulty in contouring, many structures fitted into a tight compartment, unusual chamber geometry and poor

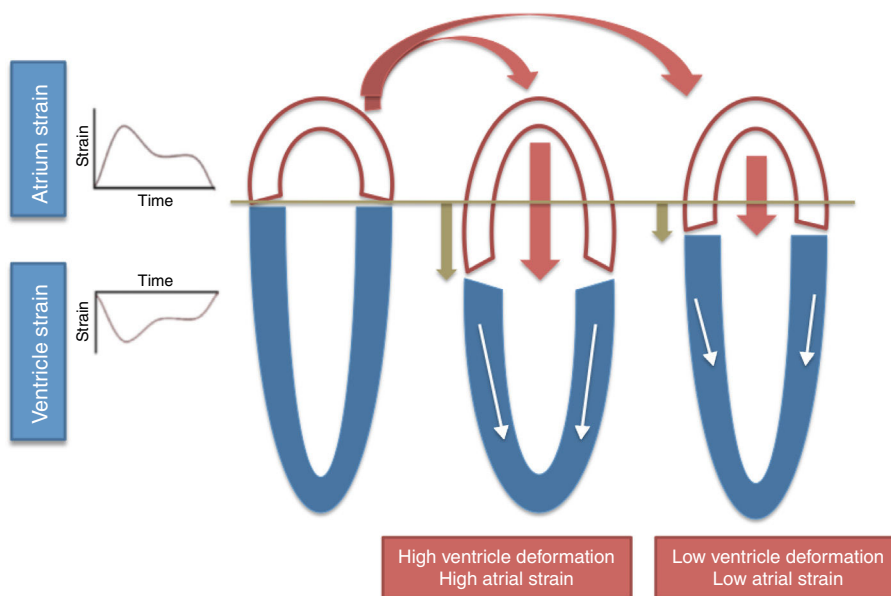


Figure 2 Interaction between right atrium strain and right ventricle strain. The white arrows indicate the strength of myocardial contraction and the crimson arrows indicates passive movement of right atrium.

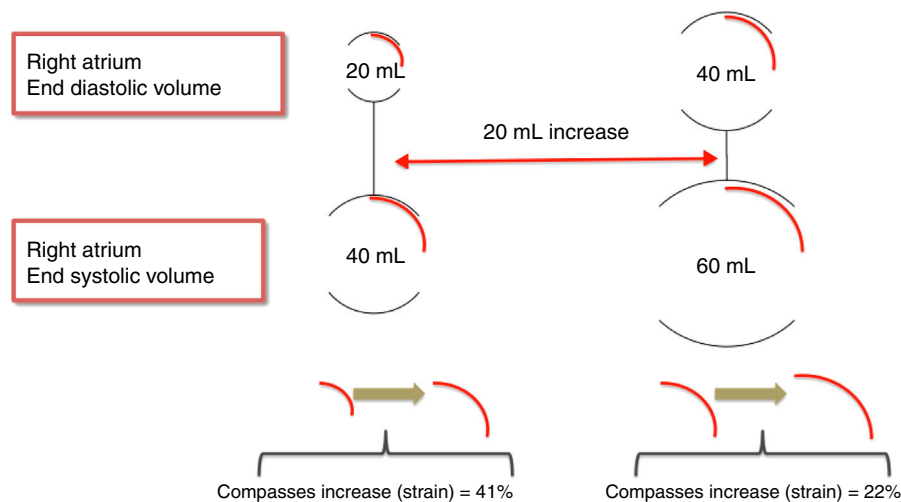


Figure 3 Interaction between right atrium size and strain.

definition due to its anterior position, and lack of commercially available software specific to the right atrium?)

Let the future clarify our souls.

Conflicts of interest

The authors have no conflicts of interest to declare.

References

- Baumgartner H, Bonhoeffer P, De Groot NM, et al., Task Force on the Management of Grown-up Congenital Heart Disease of the European Society of Cardiology (ESC); Association for European Paediatric Cardiology (AEPC); ESC Committee for Practice Guidelines (CPG). ESC Guidelines for the management of grown-up congenital heart disease (new version 2010). *Eur Heart J*. 2010;31:2915–57.
- Humenberger M, Rosenhek R, Gabriel H, et al. Benefit of atrial septal defect closure in adults: impact of age. *Eur Heart J*. 2011;32:553–60.
- Kaya Y, Yurtdas M, Ceylan Y, et al. Percutaneous closure of secundum atrial septal defects in pediatric and adult patients: short- and mid-term follow-up results. *Turk Kardiyol Dern Ars*. 2013;41:705–13.
- Di Salvo G, Drago M, Pacileo G, et al. Atrial function after surgical and percutaneous closure of atrial septal defect: a strain rate imaging study. *J Am Soc Echocardiogr*. 2005;18:930–3.
- Sirbu C, Herbots L, D’Hooge J, et al. Feasibility of strain and strain rate imaging for the assessment of regional left atrial deformation: a study in normal subjects. *Eur J Echocardiogr*. 2006;7:199–208.
- Ojaghi Haghighi Z, Naderi N, Amin A, et al. Quantitative assessment of right atrial function by strain and strain rate imaging in patients with heart failure. *Acta Cardiol*. 2011;66:737–42.
- D’Andrea A, Scarafilo R, Riegler L, et al. Right atrial size and deformation in patients with dilated cardiomyopathy undergoing cardiac resynchronization therapy. *Eur J Heart Fail*. 2009;11:1169–77.
- Wang Y, Zhang Y, Ma C, et al. Evaluation of left and right atrial function in patients with coronary slow-flow phenomenon using two-dimensional speckle tracking echocardiography. *Echocardiography*. 2016;33:871–80.
- To AH, Lai CT, Wong SJ, et al. Right atrial mechanics long-term after biventricular repair of pulmonary atresia or stenosis with intact ventricular septum. *Echocardiography*. 2016;33:586–95.
- Nemes A, Havasi K, Domsik P, et al. Evaluation of right atrial dysfunction in patients with corrected tetralogy of Fallot using 3D speckle-tracking echocardiography. Insights from the CSONGRAD Registry and MAGYAR-Path Study. *Herz*. 2015;40:980–8.
- Teixeira R, Monteiro R, Garcia J, et al. The relationship between tricuspid regurgitation severity and right atrial mechanics: a speckle tracking echocardiography study. *Int J Cardiovasc Imaging*. 2015;31:1125–35.
- Ramberg E, Olausson M, Jørgensen TB, et al. Right atrial and ventricular function evaluated with speckle tracking in patients with acute pulmonary embolism. *Am J Emerg Med*. 2017;35:136–43.
- Padeletti M, Cameli M, Lisi M, et al. Reference values of right atrial longitudinal strain imaging by two-dimensional speckle tracking. *Echocardiography*. 2012;29:147–52.
- Peluso D, Badano LP, Muraru D, et al. Right atrial size and function assessed with three-dimensional and speckle-tracking echocardiography in 200 healthy volunteers. *Eur Heart J Cardiovasc Imaging*. 2013;14:1106–14.
- Rai AB, Lima E, Munir F, et al. Speckle tracking echocardiography of the right atrium: the neglected chamber. *Clin Cardiol*. 2015;38:692–7.
- Addetia K, Takeuchi M, Maffessanti F, et al. Simultaneous longitudinal strain in all 4 cardiac chambers: a novel method for comprehensive functional assessment of the heart. *Circ Cardiovasc Imaging*. 2016;9:e003895.
- Solomon SD, Biering-Sørensen T. LA strain when ejection fraction is preserved: a new measure of diastolic function? *JACC Cardiovasc Imaging*. 2017;10:744–6.
- Ersbøll M, Andersen MJ, Valeur N, et al. The prognostic value of left atrial peak reservoir strain in acute myocardial infarction is dependent on left ventricular longitudinal function and left atrial size. *Circ Cardiovasc Imaging*. 2013;6:26–33.
- Ozturk O, Ozturk U, Ozturk S. Assessment of right atrial function with speckle tracking echocardiography after percu-

- taneous closure of an atrial septal defect. *Rev Port Cardiol.* 2017;36:895–900.
20. Arat N, Sökmen Y, Altay H, et al. Left and right atrial myocardial deformation properties in patients with an atrial septal defect. *Echocardiography.* 2008;25:401–7.
 21. Jategaonkar SR, Scholtz W, Butz T, et al. Two-dimensional strain and strain rate imaging of the right ventricle in adult patients before and after percutaneous closure of atrial septal defects. *Eur J Echocardiogr.* 2009;10:499–502.