

IMAGE IN CARDIOLOGY

A right ventricular perforation

Uma perfuração do ventrículo direito

Sofia Lázaro Mendes*, Luís Elvas, Domingos Ramos, Mariano Pêgo



Hospitais da Universidade de Coimbra – Centro Hospitalar e Universitário de Coimbra, Coimbra, Portugal

Received 19 March 2016; accepted 13 June 2016

Available online 21 February 2017

A 73-year-old woman with non-ischemic cardiomyopathy and left bundle branch block underwent implantation of a biventricular cardioverter-defibrillator with an active fixation, single-coil right ventricular lead. The procedure was without complications.

Three weeks later, she presented to the emergency department with complaints of pleuritic chest pain and shortness of breath. Her blood pressure was 100/40 mmHg, oxygen saturation was 100% on room air and temperature was 38.2 °C. Chest auscultation was normal and revealed no adventitious sounds. A chest radiograph demonstrated progression of the right ventricular lead beyond the cardiac silhouette (Figure 1), without hemothorax. Pericardial effusion was excluded. On interrogation of the device, reduced sensing amplitude was found.

Three sets of blood cultures were drawn before initiation of antimicrobial therapy with linezolid. *Staphylococcus aureus* was subsequently isolated.

We decided to extract the device since the patient had presented with fever and blood cultures were positive. Surgical backup was arranged and the pulse generator and leads were extracted by direct traction in the operating room with close echocardiographic monitoring. There was no pericardial effusion.

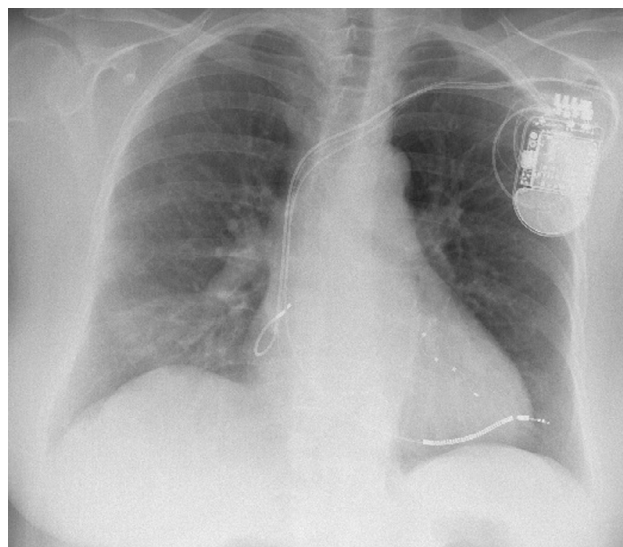


Figure 1 Chest radiography: progression of the right ventricular lead beyond the cardiac silhouette.

She remained stable and was discharged after a few weeks. Implantation of a new device was planned.

Ethical disclosures

Protection of human and animal subjects. The authors declare that no experiments were performed on humans or animals for this study.

* Corresponding author.

E-mail address: sofialazaromendes@gmail.com
(S. Lázaro Mendes).

Confidentiality of data. The authors declare that they have followed the protocols of their work center on the publication of patient data.

Right to privacy and informed consent. The authors declare that no patient data appear in this article.

Conflicts of interest

The authors have no conflicts of interest to declare.