



## IMAGE IN CARDIOLOGY

# Hanging by a thread: Major detachment of an aortic prosthetic valve



## Deiscência grave de prótese mecânica aórtica

Jennifer Mancio<sup>a,\*</sup>, Carla Almeida<sup>b</sup>, Gustavo Pires-Morais<sup>c</sup>, Lino Santos<sup>c</sup>,  
Bruno Melica<sup>c</sup>, Marco Oliveira<sup>c</sup>, Alberto Rodrigues<sup>c</sup>, Pedro Braga<sup>c</sup>, Vasco Gama Ribeiro<sup>c</sup>

<sup>a</sup> Department of Cardiology, Centro Hospitalar de Vila Nova de Gaia/Espinho and Cardiovascular R&D Unit, Department of Physiology and Cardiothoracic Surgery of Medical School of Porto, Portugal

<sup>b</sup> Department of Cardiology, Hospital do Divino Espírito Santo, Ponta Delgada, Portugal

<sup>c</sup> Department of Cardiology, Centro Hospitalar de Vila Nova de Gaia e Espinho, Vila Nova de Gaia, Portugal

Received 13 April 2015; accepted 24 July 2015

Available online 25 November 2015

### Case report

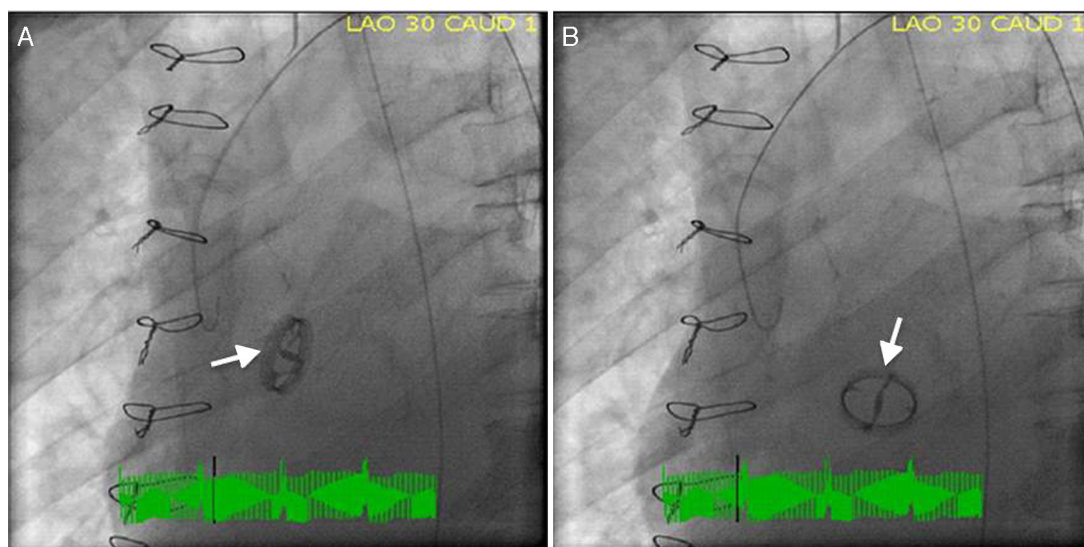
We report the case of a 62-year-old man with a previous mechanical aortic valve prosthesis who was referred for emergent cardiac catheterization after successful resuscitation from an out-of-hospital pulseless electrical activity cardiac arrest. Post-resuscitation, the patient was comatose with arterial blood pressure 60/35 mmHg, and the electrocardiogram showed widespread ST-segment depression and ST-elevation elevation in lead aVR. Mechanical ventilation, inotropic and vasopressor support were initiated during the transfer to a percutaneous coronary intervention-capable hospital. Cardiac fluoroscopy showed pivotal movement of the aortic prosthesis with each heartbeat and severe regurgitation was seen on aortography (Video 1). Prosthesis position in systole (Figure 1A) and diastole (Figure 1B) was demonstrated in individual cinefluoroscopic frames (left anterior oblique view). In diastole, the blood regurgitated into the left ventricular cavity produced a 90° clockwise rotation of the aortic prosthesis. Coronary angiography was normal. The patient underwent emergent cardiac

surgery, during which the intraoperative transesophageal echocardiogram showed a large nodular structure suggestive of vegetation at the aortic prosthesis leaflet in addition to severe aortic regurgitation (Video 2). Macroscopically, the prosthesis was found to be three-fourths detached and there were ring and perivalvular tissue vegetations with annular abscesses. Excision and replacement of the dehiscence aortic valve was performed. Methicillin-resistant *Staphylococcus epidermidis* was grown from peripheral blood and prosthetic material cultures. After completing four weeks of vancomycin therapy, the patient was discharged home asymptomatic.

Prosthetic aortic valve detachment is a rare complication, occurring in 0.1%–1.3% of patients who undergo aortic valve replacement.<sup>1</sup> The known risk factors for detachment are bacterial endocarditis, concomitant aneurysm of the ascending aorta, and severe calcification of the native aortic valve. Although echocardiography is the modality of choice for evaluating cardiac valves, assessment of mechanical prosthetic valve function by echocardiography is sometimes difficult. The value of gradients in isolation is limited, since gradients depend not only on flow magnitude but also on valve type and size.<sup>2</sup> High transprosthetic velocity alone is not proof of intrinsic aortic valve prosthesis obstruction, but may be secondary to high flow, prosthesis-patient mismatch, or pressure recovery at the smaller central valvular

\* Corresponding author.

E-mail address: [jennimancio@gmail.com](mailto:jennimancio@gmail.com) (J. Mancio).



**Figure 1** Cardiac fluoroscopy (left anterior oblique view) showing systolic (A) and diastolic (B) position of the aortic prosthesis.

orifice. Conversely, high transprosthetic gradients may not be evident in cases of low cardiac output, even in the presence of obstruction.<sup>3</sup> In cases of suspected dysfunctional prosthesis, visualization of prosthetic leaflet motion can help in differential diagnosis. However, the ability of echocardiography to visualize prosthesis disc motion is limited by the acoustic shadowing caused by the prosthetic valve itself.

Our case demonstrates that fluoroscopy permits rapid and easy evaluation of mechanical prosthetic valve function, enabling normal and dysfunctional prostheses to be distinguished. It has been demonstrated that fluoroscopy, particularly in aortic position, is superior to two-dimensional echocardiography in identifying disc motion, and so for this purpose, cinefluoroscopy is considered the gold standard technique.<sup>3</sup> In conclusion, cinefluoroscopy rapidly provides valuable information to assess prosthetic valve function which is complementary to that obtained by echocardiography.

### Ethical disclosures

**Protection of human and animal subjects.** The authors declare that no experiments were performed on humans or animals for this study.

**Confidentiality of data.** The authors declare that no patient data appear in this article.

**Right to privacy and informed consent.** The authors declare that no patient data appear in this article.

### Conflicts of interest

The authors have no conflicts of interest to declare.

### Appendix A. Supplementary material

Supplementary material associated with this article can be found in the online version at [doi:10.1016/j.repc.2015.07.009](https://doi.org/10.1016/j.repc.2015.07.009)

### References

1. Zoghbi WA, Chambers JB, Dumesnil JG, et al. Recommendations for evaluation of prosthetic valves with echocardiography and Doppler ultrasound. *J Am Soc Echocardiogr.* 2009;22:975–1014.
2. Baumgartner H, Khan S, DeRobertis M, et al. Effect of prosthetic aortic valve design on the Doppler-catheter gradient correlation: an in vitro study of normal St. Jude, Medtronic-Hall, Starr-Edwards and Hancock valves. *J Am Coll Cardiol.* 1992;19:324–32.
3. Muratori M, Montorsi P, Teruzzi G, et al. Feasibility and diagnostic accuracy of quantitative assessment of mechanical prostheses leaflet motion by transthoracic and transesophageal echocardiography in suspected prosthetic valve dysfunction. *Am J Cardiol.* 2006;97:94–100.