



CASE REPORT

Coronary artery perforation: Don't rush, IVUS may be useful



Alfonso Jurado-Román*, Julio García-Tejada, Felipe Hernández-Hernández, Carolina Granda-Nistal, María Teresa Velázquez-Martín, Agustín Albarrán González-Trevilla, Juan Tascón-Pérez

Interventional Cardiology Department, University Hospital 12 de Octubre, Madrid, Spain

Received 30 December 2014; accepted 10 March 2015

Available online 3 October 2015

KEYWORDS

Coronary artery perforation;
Covered stents;
Intravascular ultrasound

Abstract Coronary artery perforation (CAP) is a rare but potentially fatal complication of percutaneous coronary intervention. Polytetrafluoroethylene-covered stents prevent blood leakage between struts with a high rate of success. However, they lack elasticity and rapid and correct deployment is difficult. They have also a higher rate of stent restenosis and thrombosis. For these reasons, optimal deployment is essential.

Although severe CAP needs an emergent solution, after stabilizing the patient, intracoronary imaging techniques may be useful to ensure correct expansion and reduce further adverse events.

We present a case that shows the potential role of intravascular ultrasound in the resolution of a CAP.

© 2015 Sociedade Portuguesa de Cardiologia. Published by Elsevier España, S.L.U. All rights reserved.

PALAVRAS-CHAVE

Perfuração da artéria coronária;
Stents revestidos;
Ultrassonografia intravenosa

Perfuração da artéria coronária: não se precipite, a ultrassonografia intravenosa pode ser útil

Resumo A perfuração da artéria coronária (PAC) é uma complicação rara, mas potencialmente fatal da intervenção coronária percutânea (ICP). Os *stents* revestidos com politetrafluoroetileno impedem o *leakage* do sangue entre os suportes com uma elevada taxa de sucesso. No entanto, a falta de elasticidade e o posicionamento rápido e correto são difíceis. Apresentam também uma taxa mais elevada de reestenose de *stent* e de trombose. Por este motivo, é fundamental um posicionamento otimizado.

* Corresponding author.

E-mail address: alfonsojuradoroman@gmail.com (A. Jurado-Román).

Embora a PAC necessite de uma solução emergente, após estabilizar o doente, as técnicas intracoronárias imageológicas podem ser úteis para assegurar a expansão correta e reduzir eventos adversos adicionais.

Apresentamos um caso que revela o papel potencial da ultrassonografia intravenosa na resolução de uma PAC.

© 2015 Sociedade Portuguesa de Cardiologia. Publicado por Elsevier España, S.L.U. Todos os direitos reservados.

A 69-year-old patient was admitted for unstable angina. The initial ECG showed negative anterior T waves. Physical examination and laboratory tests were normal.

Forty-eight hours later, coronary angiography (CA) was performed. A severe lesion was observed in the mid left anterior descending artery (Figure 1A, arrow). A biolimus-eluting stent (3 mm×18 mm; 20 atm) was implanted, angiographic underexpansion being observed (Figure 1B,

arrow). Postdilatation with a non-compliant balloon (3 mm×15 mm; 22 atm) was performed. Immediately, the patient suffered intense chest pain and a coronary artery perforation (CAP) was observed at the proximal edge of the stent (Figure 1C). Bivalirudin was stopped, prolonged balloon inflation proximal to the perforation was performed and a covered stent (2.5 mm×18 mm) was implanted. The patient suffered tamponade and cardiac arrest which

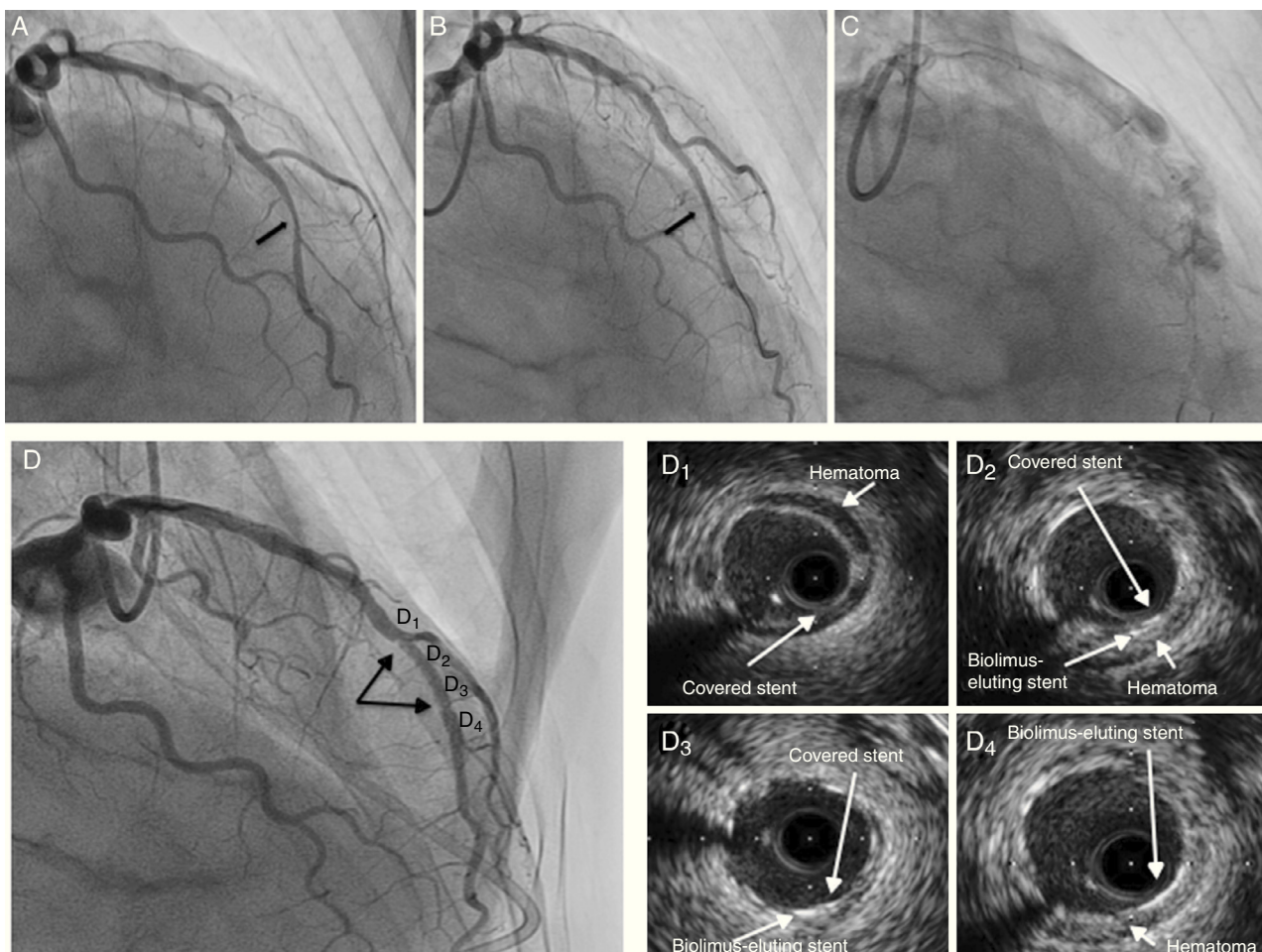


Figure 1 (A) Coronary angiography (right anterior oblique view) showing a severe lesion in the mid left anterior descending artery (arrow); (B) underexpanded biolimus-eluting stent (arrow); (C) coronary artery perforation after postdilatation with non-compliant balloon; (D) coronary angiography after hemodynamic stabilization showing probable underexpansion of the covered stent (arrows); (D1–4) intravascular ultrasound after postdilatation with non-compliant balloon: (D1) segment with a well-expanded covered stent and hematoma outside the lumen; (D2 and 3) segment with two layers of stent (covered stent and biolimus-eluting stent); (D4) segment with a biolimus-eluting stent only.

required emergent pericardiocentesis and cardiac resuscitation. After stabilization a new CA showed probable underexpansion of the covered stent (Figure 1D, arrows). Postdilatation with a non-compliant balloon was performed (3 mm×15 mm; 22 atm), and intravascular ultrasound (IVUS) confirmed correct expansion (Figure 1D, 1–4; Video 1). The patient was promptly extubated and discharged. We performed a clinical follow-up, and more than one year later, he remains asymptomatic with no adverse events.

CAP is a rare (0.43%)¹ but potentially fatal complication of percutaneous coronary intervention. The most reproducible risk factors are oversizing of devices (balloons or stents), female gender, advanced age, atheroablative devices, and treatment of complex lesions.^{1,2} Morbidity and mortality vary directly with Ellis classification: tamponade and mortality rates range between 0.4% and 0.3% (Ellis class I) to 45.7% and 21.2% (Ellis class III), respectively.^{1,3}

The poor prognosis associated with severe CAP emphasizes the importance of taking measures to prevent this complication. Awareness of risk factors, careful guidewire selection, and avoidance of balloon overexpansion remain the mainstays of CAP prevention.

There is no uniform treatment for CAP. A variety of major management strategies, based on little evidence, have been used, including observation, heparin reversal, platelet transfusion, prolonged balloon inflation, covered stent implantation, distal embolization, pericardiocentesis, and surgery.¹ Continuous monitoring is essential since deterioration can occur up to 24–48 hours afterwards. Echocardiography studies should be performed serially.

Polytetrafluoroethylene-covered stents prevent blood leakage between stent struts, and a high rate of success has been reported. However, they have some limitations: they lack elasticity and rapid and correct deployment in calcified arteries, in which the majority of perforations occur, can be difficult.¹ In addition, higher rates of stent restenosis and

thrombosis have been described compared with bare-metal stents and drug-eluting stents, and they also have higher rates of adverse events in long-term follow-up.^{1,2}

After stabilizing the patient, we should not rush, because, in cases like ours, intracoronary imaging techniques such as IVUS may be useful to ensure correct expansion and reduce further adverse events.

Ethical disclosures

Protection of human and animal subjects. The authors declare that no experiments were performed on humans or animals for this study.

Confidentiality of data. The authors declare that no patient data appear in this article.

Right to privacy and informed consent. The authors declare that no patient data appear in this article.

Conflicts of interest

The authors have no conflicts of interest to declare.

References

1. Hendry C, Fraser D, Eichhofer J, et al. Coronary perforation in the drug-eluting stent era: incidence, risk factors, management and outcome: the UK experience. *Eurointervention*. 2012;8:79–86.
2. Al-Lamee R, Ielasi A, Latib A, et al. Incidence, predictors, management, immediate and long-term outcomes following grade III coronary perforation. *JACC Cardiovasc Interv*. 2011;4:87–95.
3. Ellis SG, Ajluni S, Arnold AZ, et al. Increased coronary perforation in the new device era. Incidence, classification, management, and outcome. *Circulation*. 1994;90:2725–30.