



IMAGE IN CARDIOLOGY

A rare case of congenital aneurysm of the right atrium



Um caso raro de aneurisma congénito da aurícula direita

Alexandra da Silva Castro^{a,*}, Nuno Ferreira^b, Ricardo Ferraz^c, Nuno Bettencourt^b,
João Carlos Mota^c, Vasco Gama Ribeiro^b

^a Cardiology Department, Tâmega Sousa Hospital Centre, Penafiel, Portugal

^b Cardiology Department, Vila Nova de Gaia/Espinho Hospital Centre, Vila Nova de Gaia, Portugal

^c Cardiothoracic Surgery Department, Vila Nova de Gaia/Espinho Hospital Centre, Vila Nova de Gaia, Portugal

Received 19 January 2014; accepted 2 February 2014

Available online 18 September 2014

We report the case of a 58-year-old hypertensive man referred for a cardiology consultation due to atypical chest pain. The clinical examination was unremarkable. An electrocardiogram demonstrated sinus rhythm and incomplete right bundle branch block. He had an ambulatory echocardiogram that was described as normal. An exercise test was negative for ischemia and showed intermittent complete right bundle branch block. To exclude coronary disease a contrast computed tomography (CT) scan was performed that revealed a saccular aneurysm of the lateral free wall of the right atrium measuring 45 mm×45 mm×43 mm (Figures 1 and 2). There was no evidence of coronary disease. Given the CT findings, transthoracic echocardiography was repeated and revealed a cystic, pulsatile structure in continuity with the free wall of the right atrium through a narrow neck (Figure 3) permitting low-speed two-way flow, subsequently confirmed by injection of Sonovue[®] contrast. No cardiac thrombi were visualized. The tricuspid valvular apparatus and right ventricle were morphologically normal, as was biventricular systolic function. Similar findings were visualized on the transesophageal echocardiogram.

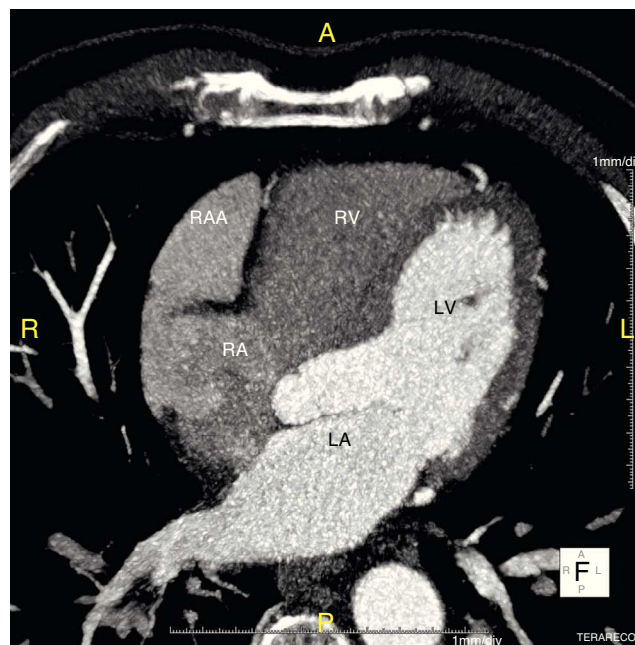


Figure 1 Computed tomography (CT) scan, axial view. LA: left atrium; LV: left ventricle; RA: right atrium; RAA: right atrial aneurysm; RV: right ventricle.

* Corresponding author.

E-mail address: alexecas@hotmail.com (A. da Silva Castro).

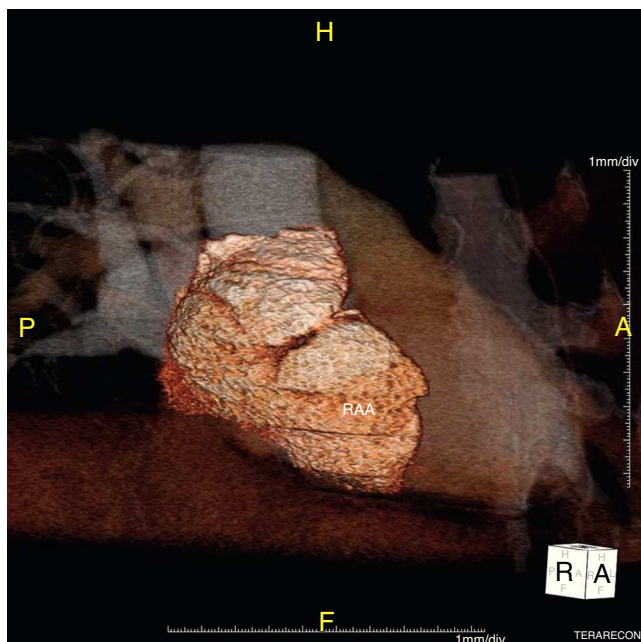


Figure 2 CT scan: three-dimensional reconstruction of the right atrial aneurysm (RAA).

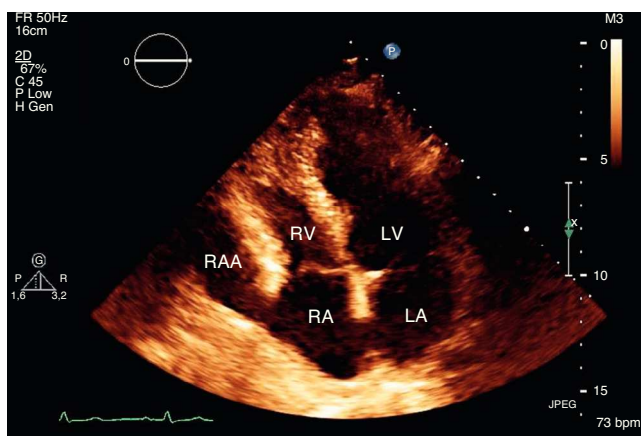


Figure 3 Transthoracic echocardiogram, apical 4-chamber view. LA: left atrium; LV: left ventricle; RA: right atrium; RAA: right atrial aneurysm; RV: right ventricle.

Right atrium aneurysm is a rare congenital heart malformation. It occurs in all age groups. Supraventricular arrhythmias and embolic events are the most common reported symptoms. Major complications such as rhythm

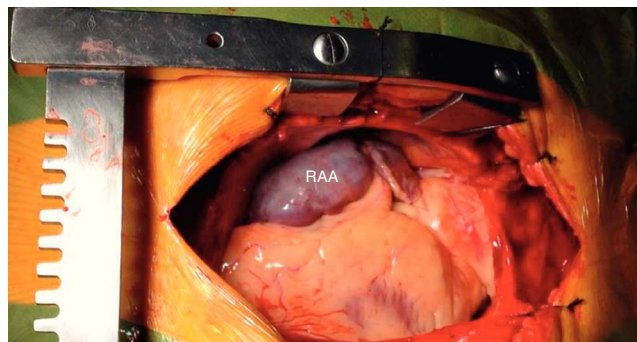


Figure 4 Intraoperative photograph (surgeon's view) revealing the right atrial aneurysm (RAA).

disturbances, thromboembolic events and aneurysm rupture may occur. Although the best treatment, particularly in asymptomatic patients, has not been established, the patient was started on oral anticoagulation and proposed for surgical aneurysmectomy. He underwent successful resection of the aneurysm (Figure 4) with an uneventful post-operative period.

Ethical disclosures

Protection of human and animal subjects. The authors declare that no experiments were performed on humans or animals for this study.

Confidentiality of data. The authors declare that they have followed the protocols of their work center on the publication of patient data.

Right to privacy and informed consent. The authors have obtained the written informed consent of the patients or subjects mentioned in the article. The corresponding author is in possession of this document.

Conflicts of interest

The authors have no conflicts of interest to declare.