



## CASE REPORT

# Steroid-induced recurrent myocardial ischemia



Ufuk Yildirim\*, Okan Gulel, Korhan Soylu, Serkan Yuksel, Mahmut Sahin

Ondokuz Mayıs University, Faculty of Medicine, Department of Cardiology, Samsun, Turkey

Received 31 December 2013; accepted 17 February 2014  
Available online 22 August 2014

### KEYWORDS

Steroid;  
Prednisolone;  
Myocardial ischemia;  
Myocardial infarction;  
Coronary slow flow

**Abstract** We report the case of a female patient under oral prednisolone therapy due to a diagnosis of idiopathic intracranial hypertension with papilledema. Unfortunately, short-term treatment with prednisolone caused an unusual complication in the patient, i.e., recurrent myocardial ischemia. Possible mechanisms leading to this complication were evaluated in the light of current knowledge.

© 2013 Sociedade Portuguesa de Cardiologia. Published by Elsevier España, S.L.U. All rights reserved.

### PALAVRAS-CHAVE

Esteróides;  
Prednisolona;  
Isquemia miocárdica;  
Enfarte agudo  
do miocárdio;  
Fluxo lento coronário

### Isquemia do miocárdio recorrente induzida por esteróides

**Resumo** Descrevemos o caso clínico de um paciente sob terapia prednisolona oral devido a um diagnóstico de hipertensão intracraniana idiopática com papiledema. Infelizmente, o tratamento a curto prazo com prednisolona causou uma complicação incomum no paciente, isto é, isquemia miocárdica recorrente. Os possíveis mecanismos que conduzem a esta complicação foram avaliados em função das literaturas correntes.

© 2013 Sociedade Portuguesa de Cardiologia. Publicado por Elsevier España, S.L.U. Todos os direitos reservados.

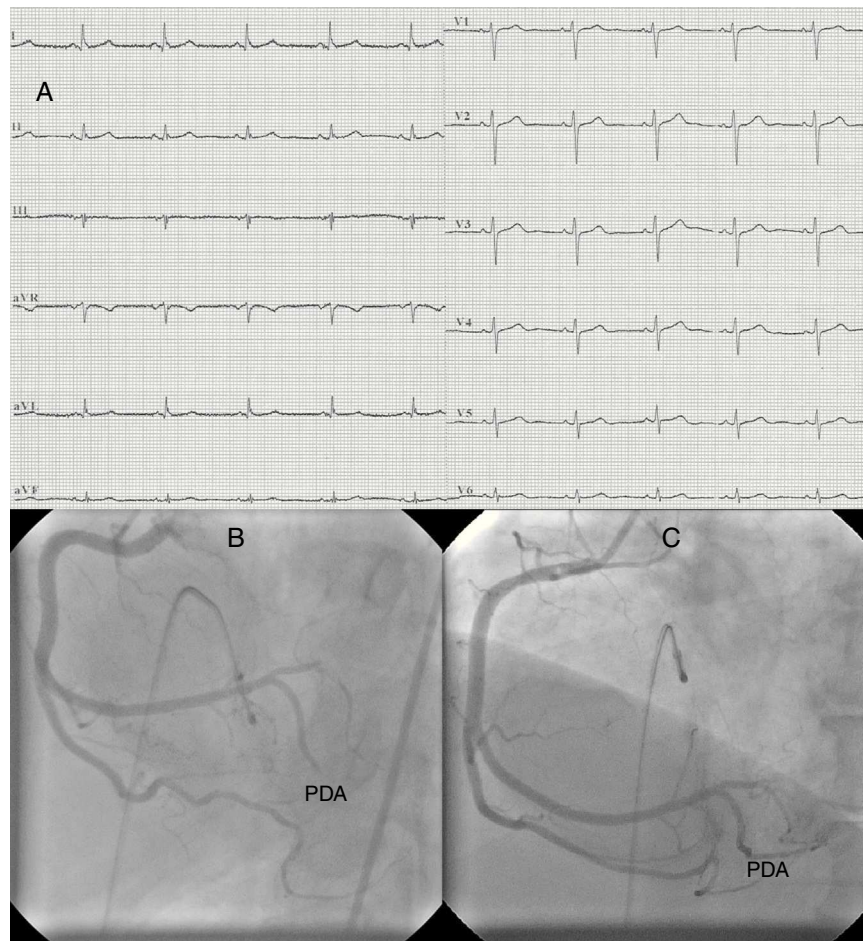
## Introduction

Glucocorticoids not only promote cardiovascular risk factors such as hypertension, insulin resistance, glucose

intolerance, dyslipidemia and obesity, but also have direct effects on the heart and blood vessels, influencing vascular function.<sup>1</sup> Here we describe a female patient under oral prednisolone therapy due to a diagnosis of idiopathic intracranial hypertension with papilledema. Unfortunately, short-term treatment with prednisolone caused an unusual complication in the patient, i.e., recurrent myocardial ischemia.

\* Corresponding author.

E-mail address: [ufukyildirim2715@yahoo.com.tr](mailto:ufukyildirim2715@yahoo.com.tr) (U. Yildirim).



**Figure 1** (A) ECG at first admission; (B) right coronary angiography during first myocardial infarction showing total occlusion of the mid portion of the posterior descending artery (PDA); (C) right coronary angiography during first myocardial infarction after percutaneous coronary intervention to the PDA.

## Case report

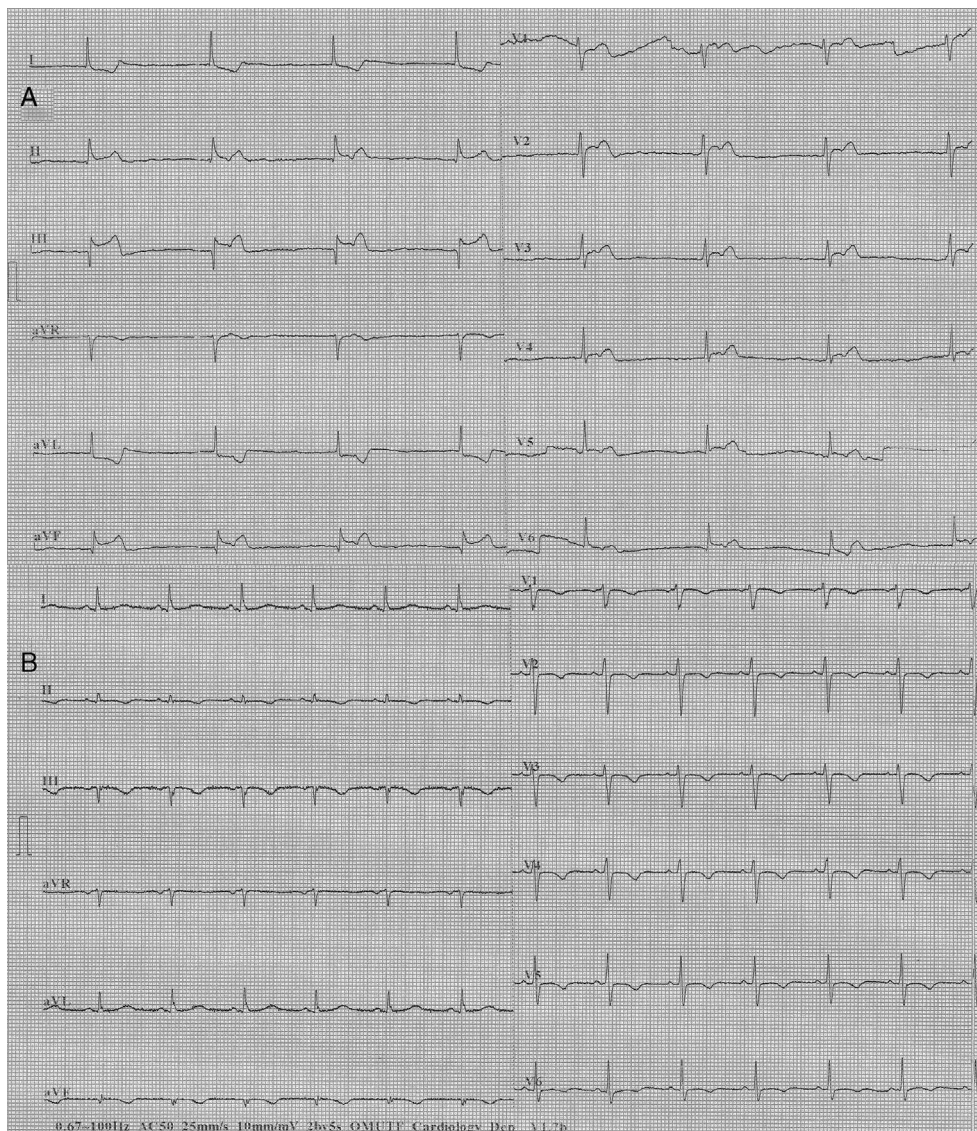
A 64-year-old woman with a history of hyperlipidemia had recurrent episodes of anginal chest pain at rest and with exertion within one month of starting oral prednisolone (40 mg/day). Her chest pain was not resolved by oral nitroglycerine. The resting electrocardiogram (ECG) showed normal sinus rhythm and revealed no ischemic changes (Figure 1A). Diagnostic coronary angiography (CAG) showed no obstructive atherosclerotic lesions, but slow flow was present in the right coronary artery (RCA). She was discharged from the hospital medicated with aspirin (100 mg/day) and diltiazem (90 mg/day).

Two weeks after the first admission, she was again admitted to the emergency department with severe anginal chest pain. The ECG showed nodal rhythm with a heart rate of 40 bpm, ST-segment elevation in leads II, III, aVF and ST-segment depression in leads I and aVL. She was urgently transferred to the cardiac catheterization laboratory. This time, interestingly, CAG showed that the mid portion of the posterior descending artery (PDA) of the RCA was totally occluded (Figure 1B). When a floppy guidewire was passed from the totally occluded PDA, the thrombus moved distally and TIMI III flow was obtained (Figure 1C). At follow-up in the

intensive care unit, the ECG returned to sinus rhythm with resolution of the ST segment changes. Pathological Q waves did not develop, but troponin I was elevated at 12 ng/ml (reference: 0–0.2 ng/ml).

Four days after myocardial infarction (MI), the patient again suffered from severe anginal chest pain. The ECG revealed similar abnormalities to those of four days previously (i.e., nodal rhythm, ST-segment elevation in leads II, III and aVF, and ST-segment depression in leads I and aVL) (Figure 2A). With intravenous atropine (1 mg) and isotonic saline infusion, sinus rhythm was restored and blood pressure was normalized. CAG showed that the PDA was open. But this time, there was slow flow in the left anterior descending coronary artery. At follow-up, the ECG showed pathological Q waves and T-wave inversions in leads II, III, and aVF. Additionally, T-wave inversions developed in the anterior precordial leads (Figure 2B). Troponin I was elevated at 41 ng/ml. Transthoracic echocardiography revealed wall motion abnormalities in the left ventricular inferior and posterior walls. There was no thrombus in the cardiac chambers and the interatrial septum was intact, without passage of agitated saline. There was no abnormal mass related to the heart valves and blood tests revealed no coagulation disorder.





**Figure 2** (A) ECG during second myocardial infarction; (B) ECG after recurrent ischemic events.

The possibility was raised that the patient's recurrent myocardial ischemia might be related to her steroid use. Therefore, after neurology consultation, oral prednisolone was stopped. She continued to receive oral acetazolamide therapy prescribed previously. After discontinuation of prednisolone, anginal chest pains did not recur. The patient was subsequently discharged from the hospital uneventfully and has remained asymptomatic for one and a half years. After discharge, her cardiovascular medications were aspirin (100 mg/day), clopidogrel (75 mg/day), atorvastatin (40 mg/day) and long-acting nifedipine (30 mg/day).

## Discussion

In this case report, the patient had recurrent episodes of anginal chest pain at rest and with exertion after short-term treatment with oral prednisolone. Although only slow flow was found at the first CAG, she had two consecutive episodes

of MI at follow-up. Since anginal chest pain and infarction did not recur after discontinuation of prednisolone, it was thought that the recurrent myocardial ischemia might be related to steroid use. What are the possible pathophysiological explanations for this hypothesis?

It has been shown that high-dose dexamethasone increases soluble P-selectin, a platelet activator, and von Willebrand factor, which is a prothrombotic marker.<sup>2</sup> Similarly, short-term dexamethasone use is associated with an increase in clotting factor levels (factors VII, VIII, XI) and fibrinogen.<sup>3</sup> Patients with excess cortisol have increased platelet count and tissue plasminogen activator inhibitor-1, but they have decreased plasma tissue factor pathway inhibitor.<sup>4</sup> This hypercoagulable and hypofibrinolytic state may increase the risk for atherosclerotic and atherothrombotic complications, as in our patient. The relative risk for the occurrence of a cardiovascular event among patients using high-dose glucocorticoids ( $\geq 7.5$  mg/day) was 2.56.<sup>5</sup> Similarly, another study showed increased risk of acute

myocardial infarction with corticosteroid use, with a greater risk observed among users of high doses (>10 mg/day).<sup>6</sup> Our patient was taking oral prednisolone 40 mg/day.

Coronary spasm may be induced by corticosteroids. It has been reported that nitrate, nitrite and nitric oxide release is decreased by cortisol treatment in a dose-dependent manner due to decreased ATP-induced intracellular calcium mobilization.<sup>7</sup> Additionally, endothelial nitric oxide synthase degradation is increased, leading to decreased endothelial nitric oxide synthase protein levels.<sup>7</sup> Glucocorticoids reduce endothelial nitric oxide synthase mRNA stability,<sup>8</sup> inhibit the synthesis of tetrahydrobiopterin, an important cofactor of endothelial nitric oxide synthase,<sup>9</sup> and suppress the production of the vasodilator prostacyclin by downregulating cyclooxygenase-1 gene expression.<sup>10</sup> On the other hand, they increase the synthesis of the vasoconstrictor thromboxane.<sup>11</sup> Sustained elevation of serum cortisol levels might lead to sensitization of coronary vasoconstricting responses through Rho-kinase activation,<sup>12</sup> while oral cortisol administration impairs cholinergic vasodilation even in healthy normotensive subjects.<sup>13</sup> All these mechanisms may reduce coronary blood flow by increasing contraction of coronary arteries. There are a few case reports in the literature reporting the occurrence of coronary spasm following corticosteroid administration.<sup>14</sup>

Short-term use of oral prednisolone in our patient may have led to endothelial dysfunction, increased microvascular resistance, coronary vasospasm, reduced coronary flow reserve, coronary slow flow, increased thrombogenicity, and eventually recurrent myocardial ischemia.

## Conclusion

Drugs containing steroids have many side effects involving the cardiovascular system. It should be borne in mind that their use may trigger recurrent myocardial ischemia in some patients.

## Ethical disclosures

**Protection of human and animal subjects.** The authors declare that no experiments were performed on humans or animals for this study.

**Confidentiality of data.** The authors declare that they have followed the protocols of their work center on the publication of patient data.

**Right to privacy and informed consent.** The authors have obtained the written informed consent of the patients or

subjects mentioned in the article. The corresponding author is in possession of this document.

## Conflicts of interest

The authors have no conflicts of interest to declare.

## References

1. Walker BR. Glucocorticoids and cardiovascular disease. *Eur J Endocrinol.* 2007;157:545–59.
2. Jilma B, Cvitko T, Winter-Fabry A, et al. High dose dexamethasone increases circulating P-selectin and von Willebrand factor levels in healthy men. *Thromb Haemost.* 2005;94:797–801.
3. Brotman DJ, Girod JP, Posch A, et al. Effects of short-term glucocorticoids on hemostatic factors in healthy volunteers. *Thromb Res.* 2006;118:247–52.
4. Erem C, Nuhoglu I, Yilmaz M, et al. Blood coagulation and fibrinolysis in patients with Cushing's syndrome: increased plasminogen activator inhibitor-1, decreased tissue factor pathway inhibitor, and unchanged thrombin-activatable fibrinolysis inhibitor levels. *J Endocrinol Invest.* 2009;32:169–74.
5. Wei L, MacDonald TM, Walker BR. Taking glucocorticoids by prescription is associated with subsequent cardiovascular disease. *Ann Intern Med.* 2004;141:764–70.
6. Varas-Lorenzo C, Rodriguez LA, Maguire A, et al. Use of oral corticosteroids and the risk of acute myocardial infarction. *Atherosclerosis.* 2007;192:376–83.
7. Rogers KM, Bonar CA, Estrella JL, et al. Inhibitory effect of glucocorticoid on coronary artery endothelial function. *Am J Physiol Heart Circ Physiol.* 2002;283:H1922–8.
8. Wallerath T, Witte K, Schäfer SC, et al. Down-regulation of the expression of endothelial NO synthase is likely to contribute to glucocorticoid-mediated hypertension. *Proc Natl Acad Sci U S A.* 1999;96:13357–62.
9. Johns DG, Dorrance AM, Tramontini NL, et al. Glucocorticoids inhibit tetrahydrobiopterin-dependent endothelial function. *Exp Biol Med (Maywood).* 2001;226:27–31.
10. Jun SS, Chen Z, Pace MC, et al. Glucocorticoids down-regulate cyclooxygenase-1 gene expression and prostacyclin synthesis in fetal pulmonary artery endothelium. *Circ Res.* 1999;84:193–200.
11. Fimognari FL, Piccirillo G, Lama J, et al. Associated daily biosynthesis of cortisol and thromboxane A2: a preliminary report. *J Lab Clin Med.* 1996;128:115–21.
12. Hizume T, Morikawa K, Takaki A, et al. Sustained elevation of serum cortisol level causes sensitization of coronary vasoconstricting responses in pigs in vivo: a possible link between stress and coronary vasospasm. *Circ Res.* 2006;99:767–75.
13. Mangos GJ, Walker BR, Kelly JJ, et al. Cortisol inhibits cholinergic vasodilation in the human forearm. *Am J Hypertens.* 2000;13:1155–60.
14. Okumura W, Nakajima M, Tateno R, et al. Three cases of vasospastic angina that developed following the initiation of corticosteroid therapy. *Intern Med.* 2014;53:221–5.