

IMAGE IN CARDIOLOGY

Mediastinal hydatid cyst compressing the pulmonary artery and atrial septal defect: A rare association



Cisto hidático do mediastino comprimindo a artéria pulmonar e defeito septal auricular – uma associação rara

Arif Suner^a, Sedat Koroglu^{b,*}, Musa Cakici^a, Mustafa Polat^a, Mustafa Cetin^a, Bulent Petik^c, Recai Kaya^d, Hakan Kaya^a

^a Adiyaman University, Education and Research Hospital, Cardiology Clinic, Adiyaman, Turkey

^b Afsin State Hospital, Cardiology Clinic, Kahramanmaraş, Turkey

^c Adiyaman University, Education and Research Hospital, Radiology Clinic, Adiyaman, Turkey

^d Adiyaman University, Education and Research Hospital, Anesthesiology Clinic, Adiyaman, Turkey

Received 6 November 2013; accepted 28 November 2013

Available online 2 June 2014

A 21-year-old woman was admitted to our clinic with dyspnea. Her medical history was unremarkable. Right bundle branch block was identified on 12-lead ECG and mediastinal enlargement on the chest X-ray. Transthoracic and transesophageal echocardiographic examination showed a lobulated cystic image in the left atrium and secundum-type atrial septal defect (Figures 1 and 2). Addi-

tionally, in short-axis view a mass was visualized invading the pulmonary artery, and continuous wave Doppler of the pulmonary artery revealed a maximum gradient of 40 mmHg. A detailed examination with cardiac magnetic resonance imaging demonstrated a multicystic mass in the mediastinum compressing the main pulmonary artery, predominantly the left branch (Figure 3). The patient was

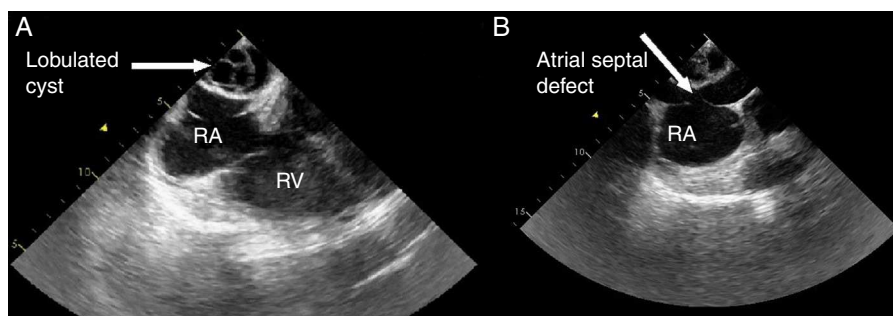


Figure 1 Transesophageal echocardiographic views showing (A) lobulated cyst and (B) atrial septal defect. RA: right atrium; RV: right ventricle.

* Corresponding author.

E-mail address: k.sedat@mynet.com (S. Koroglu).

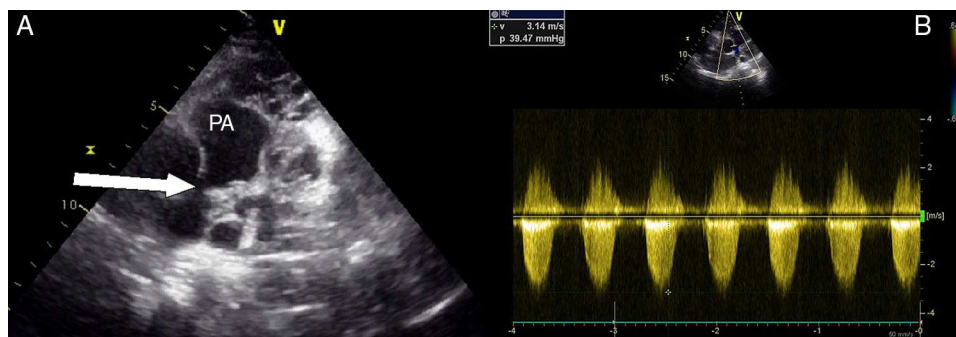


Figure 2 Transthoracic echocardiographic views showing (A) multiple cystic mass compressing the pulmonary artery and (B) continuous wave Doppler of the pulmonary artery with maximum gradient of 40 mmHg. PA: pulmonary artery.

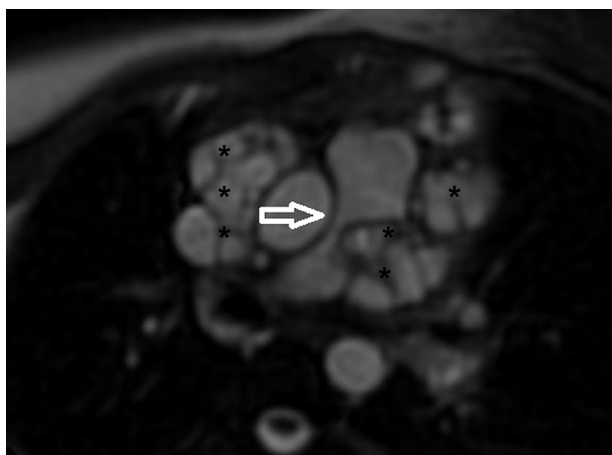


Figure 3 Cardiac magnetic resonance imaging showing external compression of pulmonary artery. Black asterisks indicate hydatid cysts.

diagnosed with secundum atrial septal defect and mediastinal hydatid cyst on the basis of serologic tests and detailed history. Surgical therapy was offered and she asked for time to think. Medication with albendazole was started, but she was then lost to follow-up.

Hydatid cyst is a parasitic disease caused by *Echinococcus granulosus*. The predominantly affected organs are the liver and the lung; mediastinal location is very rare.¹ The

preferred method for management is surgery but adjunctive albendazole therapy is the subject of debate.

Ethical disclosures

Protection of human and animal subjects. The authors declare that no experiments were performed on humans or animals for this study.

Confidentiality of data. The authors declare that they have followed the protocols of their work center on the publication of patient data.

Right to privacy and informed consent. The authors have obtained the written informed consent of the patients or subjects mentioned in the article. The corresponding author is in possession of this document.

Conflicts of interest

The authors have no conflicts of interest to declare.

Reference

1. Isitmangil T, Toker A, Sebit S, et al. A novel terminology and dissemination theory for a subgroup of intrathoracic extrapulmonary hydatid cysts. *Med Hypotheses*. 2003;61:68–71.