



IMAGE IN CARDIOLOGY

Chest stab wound—A rare cause of late ventricular tachycardia

Lesão miocárdica por ferimento de arma branca – uma causa rara de taquicardia ventricular tardia

Sílvia Ribeiro^{a,*}, Nuno Salomé^a, Teresa Pinho^b, Helena Gonçalves^c, João Primo^c, Pedro Azevedo^a, Adelino Correia^a

^a Serviço de Cardiologia, Hospital de Braga, Braga, Portugal

^b Serviço de Cardiologia, Hospital de São João, Porto, Portugal

^c Serviço de Cardiologia, Centro Hospitalar de Vila Nova de Gaia/Espinho, Vila Nova de Gaia, Portugal

Received 10 May 2012; accepted 27 May 2012

Available online 21 December 2012

A 67-year-old man with a history of systemic arterial hypertension and a chest stab trauma with emergent cardiothoracic surgery 38 years previously was admitted to our cardiology department for sustained monomorphic ventricular tachycardia.

At admission to the emergency department the patient complained of palpitations, sweating and general malaise. He was hemodynamically stable. The admission electrocardiogram showed regular wide complex tachycardia with right bundle branch block pattern consistent with ventricular tachycardia (Figure 1A). Chemical cardioversion with amiodarone was successfully performed. The baseline ECG demonstrated sinus rhythm with Q waves in DI, aVL and V3–V6. Laboratory tests, including troponin, were unremarkable. The transthoracic echocardiogram revealed normal global left ventricular systolic function with anterolateral hypokinesia. Coronary angiography excluded

epicardial coronary disease. Cardiac magnetic resonance imaging revealed transmural gadolinium enhancement in the mid-apical anterior and lateral segments consistent with the chest stab wound (Figure 1B). The patient was referred for electrophysiological study, during which ventricular tachycardia was induced with the same pattern as the admission ECG (Figure 1C) but it was not possible to perform ablation because of a probable epicardial circuit and an implantable cardioverter-defibrillator was implanted. The patient is currently asymptomatic.

Ventricular tachycardia is a life-threatening arrhythmia. In the majority of cases it is associated with structural heart disease, particularly coronary disease. We describe an unusual case of a 67-year-old man who survived a chest stab wound and presented 38 years later with ventricular tachycardia due to the anterolateral transmural scar.

* Corresponding author.

E-mail address: silviamartinsribeiro@gmail.com (S. Ribeiro).

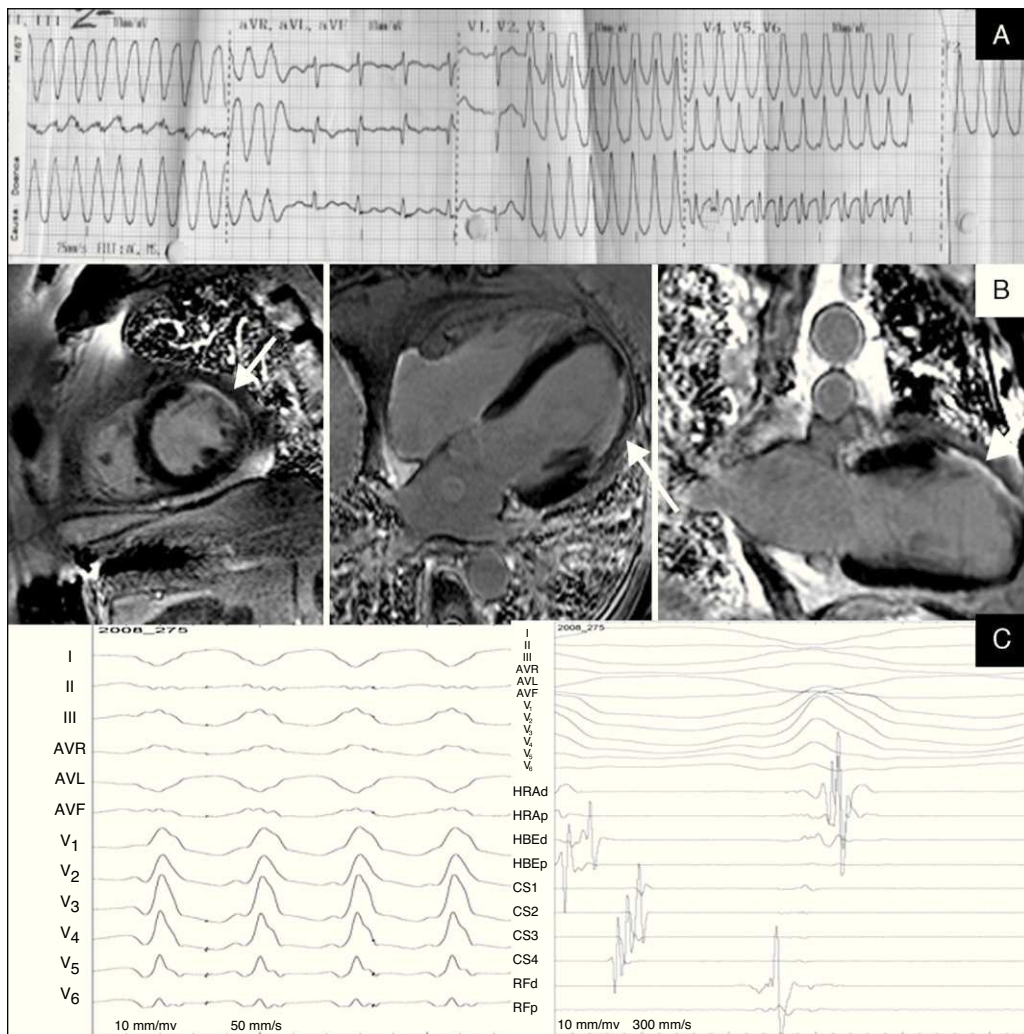


Figure 1 A) Admission ECG demonstrating a monomorphic ventricular tachycardia; B) CMR images in short axis, long axis and four-chambers views obtained after gadolinium injection demonstrating transmurular gadolinium enhancement in mid-apical anterior and lateral segments; C) morphology of ventricular tachycardia during the electrophysiological study and left ventricular endocardial mapping.

Ethical disclosures

Protection of human and animal subjects. The authors declare that no experiments were performed on humans or animals for this study.

Confidentiality of data. The authors declare that no patient data appear in this article.

Right to privacy and informed consent. The authors declare that no patient data appear in this article.

Conflicts of interest

The authors have no conflicts of interest to declare.