

## IMAGE IN CARDIOLOGY

# Twiddler syndrome as a cause of defibrillator malfunction

## Síndrome de Twiddler: causa de disfunção do desfibrilhador

Inmaculada González Bermúdez\*, Mónica Pardo Fresno, Enrique García Campo, Laura Arnáiz Betolaza, Natividad Crespo Carazo, Xulio Beiras Torrado

*Clinical Electrophysiology Unit, Department of Cardiology, Hospital Meixoeiro, Vigo, Spain*

Received 24 April 2012; accepted 6 May 2012

Available online 15 November 2012

Twiddler syndrome is a rare cause of pacing failure in pacemakers and implantable cardioverter-defibrillators that should not be neglected.

We describe a case of twiddler syndrome in a patient with a defibrillator.

A 74-year-old woman with hypertension, dyslipidemia, and obesity as cardiovascular risk factors was diagnosed with nonobstructive hypertrophic cardiomyopathy with preserved systolic function. During follow-up, she presented sustained syncopal monomorphic ventricular tachycardias and a dual-chamber cardioverter-defibrillator was accordingly implanted; both leads used passive fixation (Figure 1).

At two-month follow-up post-implantation, atrial detection and capture were absent and the ventricular threshold was three times the implant value. Ventricular sensing was preserved. The patient denied conscious manipulation of the device pocket and reported that she had noticed spontaneous rotation of the device. This was corroborated by the family.

A chest X-ray showed that the generator had rotated and that both leads had become displaced, with the atrial lead situated in the left subclavian vein (Figure 2). Surgery was performed to reposition the ventricular lead and to replace the atrial lead with an active fixation lead (Figure 3); the

generator was attached to the pectoral muscle. Subsequent follow-up was unremarkable.

Twiddler syndrome is defined as generator rotation with lead twisting and secondary malfunction of the leads. The causes of this syndrome are not always clear. However, predisposing factors include the creation of a large subcutaneous pocket, obesity, unconscious repetitive movements

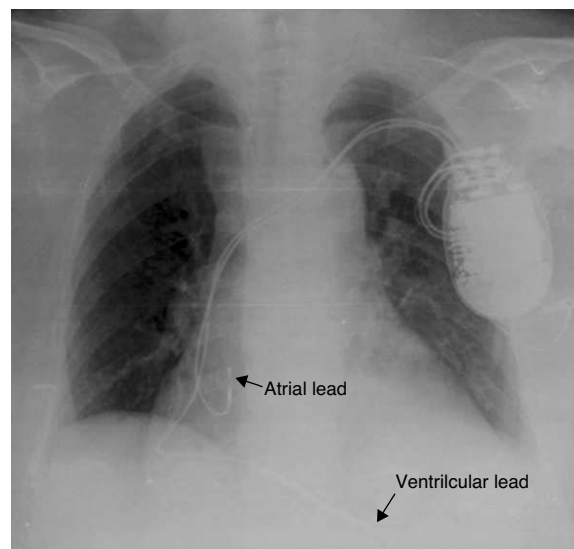
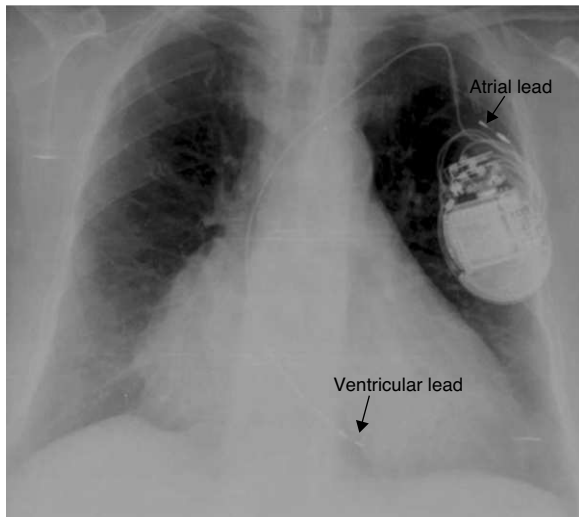


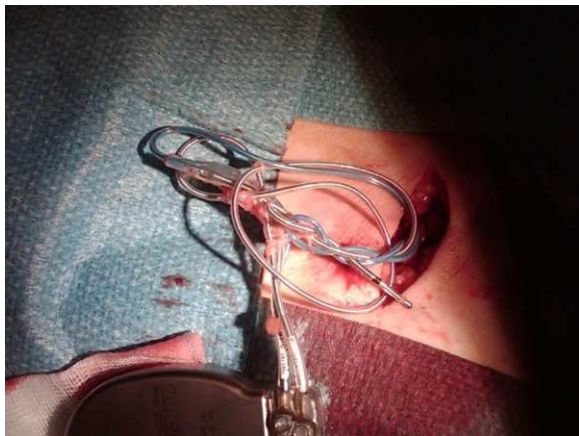
Figure 1 Initial chest X-ray after defibrillator implantation.

\* Corresponding author.

E-mail address: [inmaculada\\_glez@yahoo.es](mailto:inmaculada_glez@yahoo.es)  
(I. González Bermúdez).



**Figure 2** Chest X-ray showing displacement of both leads.



**Figure 3** Twisted leads.

of the left arm, manipulation of the pocket, or the adoption of repeated poor postural positions. We suggest that the generator be fixed to the muscle plane to prevent the generator from turning and that the patient be given detailed instructions to avoid certain postures or manipulations. The syndrome should be kept in mind, so that device malfunction can be avoided or resolved. In our patient, the atrial lead was mainly affected. In the case of defibrillators, however, inappropriate shock therapies due to incorrect device sensing deserve special attention.

### Ethical disclosures

**Protection of human and animal subjects.** The authors declare that no experiments were performed on humans or animals for this investigation.

**Confidentiality of data.** The authors declare that no patient data appear in this article.

**Right to privacy and informed consent.** The authors declare that no patient data appear in this article.

### Conflicts of interest

The authors have no conflicts of interest to declare.