

IMAGE IN CARDIOLOGY

Hoarseness

Disfonia

Sofia Lázaro Mendes*, Domingos Ramos, Mariano Pêgo



Cardiology Department, Coimbra University Hospital and Medical School, Coimbra, Portugal

Received 29 July 2015; accepted 21 November 2015

A 63-year-old man presented to the hospital with gradual-onset hoarseness of three months' duration. He had a history of smoking assessed at 58 pack-years, and no other symptoms such as cough, dyspnea or weight loss. His heart rate was 60 beats/min and blood pressure was 159/67 mmHg; the cardiac exam revealed a diastolic murmur in the aortic area. Indirect laryngoscopy revealed a paralyzed left vocal cord in paramedian position. The chest X-ray (Figure 1) showed a slight mediastinal bulge adjacent to the aortic knuckle but no pulmonary mass.

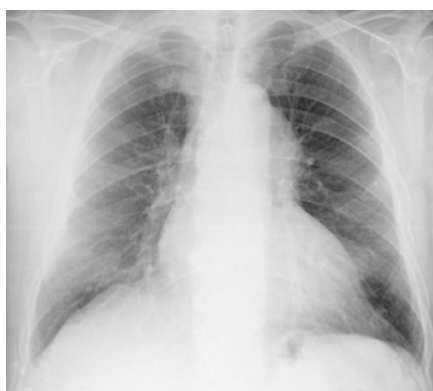

Figure 1 Chest X-ray, showing a slight mediastinal bulge adjacent to the aortic knuckle.

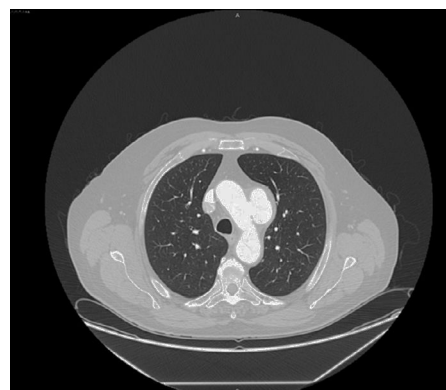


Figure 2 Contrast-enhanced thoracic computed tomography with frontal reconstruction, showing a saccular aneurysm of the aortic arch.

Contrast-enhanced thoracic computed tomography with frontal and sagittal reconstruction (Figures 2 and 3) was performed and revealed a saccular aneurysm of the aortic arch with dilatation up to 6.9 cm and partial thrombosis of the wall.

There was no tumor along the intrathoracic route of the left recurrent laryngeal nerve (RLN). The transthoracic echocardiography was normal.

The patient underwent aneurysmectomy and his postoperative course was excellent and uncomplicated, but 12 months after surgery he has not yet recovered from RLN palsy.

Thoracic saccular aortic aneurysm is an important consideration in the differential diagnosis of RLN palsy.

* Corresponding author.

E-mail address: sofialazaromendes@gmail.com (S.L. Mendes).

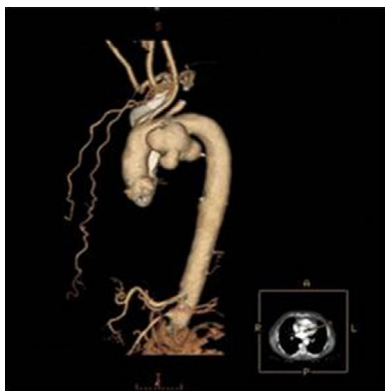


Figure 3 Contrast-enhanced thoracic computed tomography with sagittal reconstruction, showing a saccular aneurysm of the aortic arch.

Ethical disclosures

Protection of human and animal subjects. The authors declare that no experiments were performed on humans or animals for this study.

Confidentiality of data. The authors declare that they have followed the protocols of their work center on the publication of patient data.

Right to privacy and informed consent. The authors declare that no patient data appear in this article.

Conflicts of interest

The authors have no conflicts of interest to declare.