

CASE REPORT

Arterial thrombosis and acute myocardial infarction with angiographically normal coronary arteries in a woman heterozygous for both factor V Leiden and prothrombin mutation

João Gaspar^a, Cláudio Benchimol^b, Telma Gadelha^c, Guilherme Loures Penna^{d,*}

^aInternal Medicine, Hospital de Ipanema, Hospital Samaritano, Rio de Janeiro, Brazil

^bCardiology Service, Federal University of Rio de Janeiro, Hospital Samaritano, Rio de Janeiro, Brazil

^cHematology Service, Federal University of Rio de Janeiro, Hospital Samaritano, Rio de Janeiro, Brazil

^dInternal Medicine, Casa de Saúde São Jose, Hospital Samaritano, Rio de Janeiro, Brazil

Received November 12, 2010; accepted May 2, 2011

KEYWORDS

Arterial thrombosis;
Myocardial infarction;
Thrombophilia

Abstract Thirteen years after her last thrombotic event, anticoagulation was discontinued in a patient with combined thrombophilia involving mutation in factor V and G20210A polymorphism of the prothrombin gene. The only history was of arterial thrombosis. Three months later she presented a transmural myocardial infarction caused by coronary thrombosis.

© 2010 Sociedade Portuguesa de Cardiologia. Published by Elsevier España, S.L. All rights reserved.

PALAVRAS-CHAVE

Trombose arterial;
Enfarte do miocárdio;
Trombofilia

Trombose arterial e infarto agudo do miocárdio com artérias coronárias angiograficamente normais em mulher heterozigota para fator V de Leiden e mutação do gene da protrombina

Resumo Após treze anos do último evento trombótico, a anticoagulação foi interrompida numa paciente com associação de trombofilia factor V de Leiden e gene mutante da protrombina G20210A. Ela possuía história de trombozes arteriais. Três meses após a paciente apresentou enfarte transmural do miocárdio devido à trombose coronariana.

© 2010 Sociedade Portuguesa de Cardiologia. Publicado por Elsevier España, S.L. Todos os direitos reservados.

*Corresponding author:

E-mail: guipenna@terra.com.br (G.L. Penna).

Introduction

Genetic, environmental, and behavioral risk factors may interact to cause thrombosis. Factor V Leiden and the prothrombin G20210A mutation are two highly prevalent genetic variants that are well documented risk factors for venous thrombosis. The role of these gene variants in arterial events has been difficult to define. In 1997, two studies by Rosendaal et al.^{1,2} showed increased frequencies of factor V Leiden and prothrombin G20210A in young women who experienced myocardial infarction (MI). There is a probable synergic role for genetic factors in subgroups of patients presenting with environmental or behavioral factors.

Myocardial infarctions with normal (or near-normal) coronary arteries (MINCA) account for 1% to 12% of cases^{3,4}. A possible mechanism for MINCA is occlusion of the vessel lumen by thrombus that is subsequently rapidly lysed. Etiological factors that have been reported include cocaine use, embolism, coronary endothelial dysfunction and hypercoagulable states.

Case report

A 51-year-old white woman was admitted to the hospital with acute chest pain of less than 6 hours duration. The cardiological investigation showed a non-Q wave acute coronary syndrome in the anteroseptal wall that did not affect its motion, and coronary artery angiography showed a normal left anterior descending artery and an occluded distal portion of the third marginal branch of the circumflex artery. She had smoked about 20 to 40 cigarettes/day since the age of 18. No other known risk factors for coronary heart disease were present. The patient was treated with nitroglycerin infusion and an oral beta-blocker. She made a good recovery and was discharged from the hospital two days later. Seventy-two hours later, she experienced severe, squeezing, acute anterior chest pain and was readmitted

to the hospital. The ECG showed a pattern typical of a transmural acute anterior wall myocardial infarction. A new coronary angiogram (Figure) showed almost total occlusion of the descending anterior coronary artery and the second diagonal, interpreted as vessels filled with clots, with no vascular lesion (endoluminal irregularities attributed to coronary atherosclerosis). She was treated with analgesics, angioplasty of the two affected vessels without stent placement, abciximab, and a continuous venous infusion of nitroglycerin. After the cessation of abciximab, she was sequentially administered unfractionated heparin, low molecular weight heparin, and warfarin, respectively. At 5-month follow-up, she was being treated with permanent oral anticoagulants in addition to atorvastatin.

Thirteen years before, she had presented with recurrent episodes of transient arterial ischemia of the lower limbs. These arterial events resolved with the use of vasodilator medication. In April 1995, she presented with a mesenteric embolic accident of the superior mesenteric artery which was detected by mesenteric angiography. She received surgery following an embolectomy of the superior mesenteric artery, with apparent recovery of the ischemic segment of the small bowel. Forty-eight hours afterwards, she underwent a second-look operation which revealed a 150 cm, non-viable segment of her small bowel, which was resected with transit, and reconstructed with a primary anastomosis. At this time, an investigation for thrombophilic factors was performed, and she was found to be heterozygous for factor V Leiden. Two years later, she was also found to be heterozygous for the prothrombin G20210A variant. Her mother and only sister were heterozygous for factor V Leiden, but negative for prothrombin G20210A. Both her mother and sister smoke, but neither has ever experienced thrombotic events. The patient was maintained on anticoagulant treatment with warfarin for 13 years with no new thrombotic events. She was unable to stop smoking. In March 2007, we decided to discontinue the anticoagulant treatment. Three months afterwards, she presented with the ischemic heart attack.

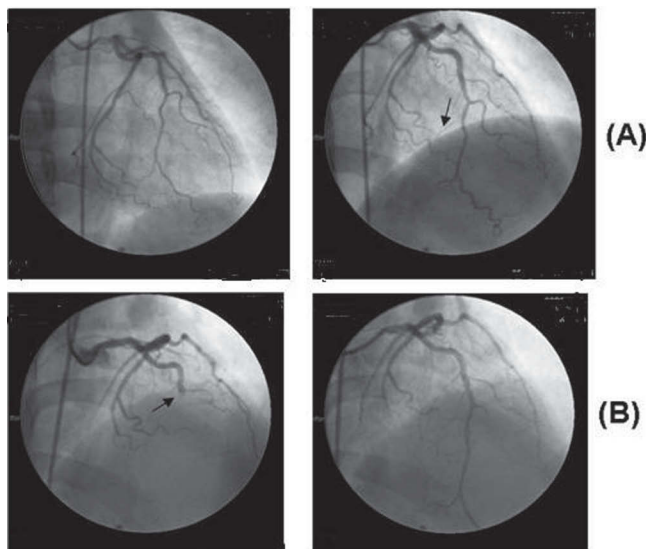


Figure Coronary angiogram showing almost total occlusion of the second diagonal (A) and the descending anterior coronary artery (B).

Discussion

The association between factor V Leiden and prothrombin G20210A and arterial events is controversial. A study of eight prothrombotic gene polymorphisms, including these two genetic variants, in 1210 patients <45 years of age showed no increased risk of premature MI⁵. Two meta-analyses⁶ did not demonstrate an association between factor V Leiden and arterial disease. Nevertheless, in a case-control study¹ of young women (aged 18-44), factor V Leiden was associated with a 2.4-fold increased risk of MI. This increased risk was limited to current smokers. There may be a small risk for arterial events associated with these genetic variants, which is considerably amplified when additional risk factors are present.

In a previously reported small series, almost all patients presenting with MINCA were males <50 years of age and regular cigarette smokers³. It has been suggested that thrombophilic factors may increase the risk of MI in patients with normal coronary angiograms more than in those with more severe coronary atherosclerosis^{1,2}. Furthermore, in

this specific cardiological situation, the frequencies of both factor V Leiden and prothrombin G20210A seemed to be higher in patients <50 years of age⁷. In another study⁸, factor V Leiden was found in 12% of young patients (mean age 44 years) with MINCA, in 4.5% of patients with MI and significant coronary artery disease, and in 5% of normal controls.

It is worth mentioning that carriers of two defects seem to be at greater risk of venous thrombosis than their relatives with a single defect⁹. A pooled analysis of eight case-control studies¹⁰ showed a venous thrombotic risk of 4.9 for factor V Leiden, 3.8 for prothrombin G20210A, and 20 for those heterozygous for both mutations.

The unusual aspect of the present case is that the patient was heterozygous for both genetic variants, but presented with no venous thrombosis, and experienced life-threatening arterial thrombotic events that occurred while she was not receiving anticoagulation.

References

1. Rosendaal FR, Siscovick DS, Schwartz SM, et al. Factor V Leiden (Resistance to Activated Protein C) increases the risk of myocardial infarction in young women. *Blood*. 1997; 89:2817-21.
2. Rosendaal FR, Siscovick DS, Schwartz SM, et al. A common prothrombin variant (20210 G to A) increases the risk of myocardial infarction in young women. *Blood*. 1997;90:1747-50.
3. Sharifi M, Frohlich TG, Silverman IM. Myocardial infarction with angiographically normal coronary arteries. *Chest*. 1995;107:36-40.
4. Alpert JS. Myocardial infarction with angiographically normal coronary arteries. *Arch Intern Med*. 1994;154:265-9.
5. Atherosclerosis, Thrombosis and Vascular Biology Italian Study Group. No evidence of association between prothrombotic gene polymorphisms and the development of acute myocardial infarction at a young age. *Circulation*. 2003;107:1117-22.
6. Jul K, Tybjaerg-Hansen A, Steffensen R, et al. Factor V Leiden: The Copenhagen City Heart Study and 2 meta-analyses. *Blood*. 2002;100:3-10.
7. Van de Water NS, French JK, Lund M, et al. Prevalence of factor V Leiden and prothrombin variant G20210A in patients age < 50 years with no significant stenoses at angiography three to four weeks after myocardial infarction. *J Am Coll Cardiol*. 2000;36:717-22.
8. Mansourati J, Da Costa A, Munier S, et al. Prevalence of factor V Leiden in patients with myocardial infarction and normal coronary angiography. *Thromb Haemost*. 2000;83:822-5.
9. Koeleman BPC, Reitsma PH, Bertina RM. Familial thrombophilia: A complex genetic disorder. *Semin Hematol*. 1997;34:256-64.
10. Emmerich J, Rosendaal FR, Cattaneo M, et al. Combined effect of factor V Leiden and prothrombin 20210A on the risk of venous thromboembolism. *Thromb Haemost*. 2001;86:809-16.